



# Mechanical, biological and clinical aspects of zirconia implants

**Eric Van Dooren, DDS**

Private Practice, Antwerp, Belgium

**Marcelo Calamita, DDS, MSc, PhD**

Private Practice, Sao Paulo, Brazil

**Murilo Calgato, DMT**

Sao Paulo, Brazil

**Christian Coachman, DDS, DMT**

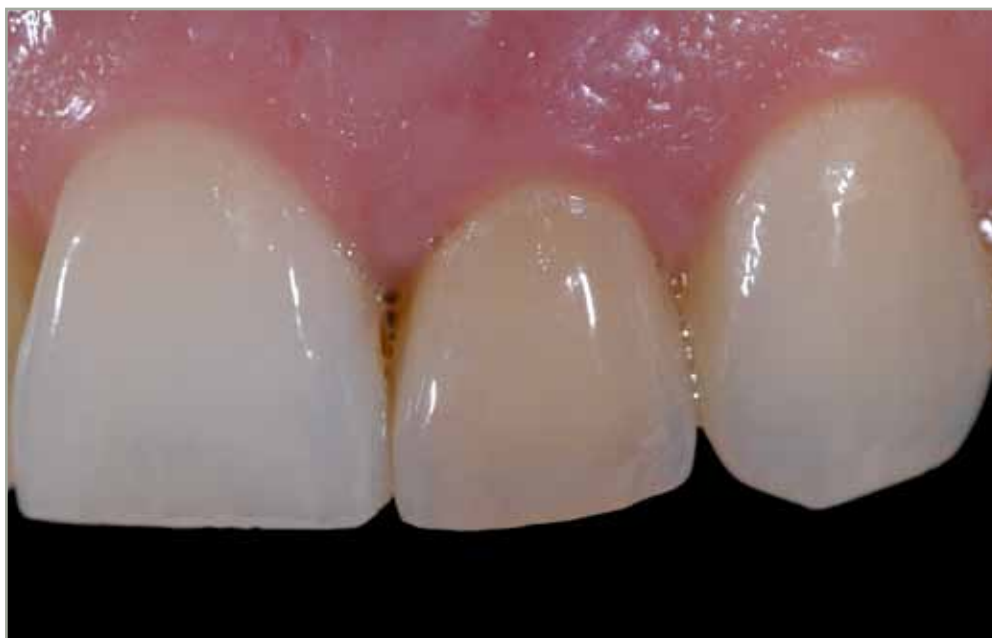Private Practice, Sao Paulo, Brazil

**Jonathan L. Ferencz, DDS**

Private Practice, New York, USA

**Nelson RFA Silva, DDS, MSc, PhD**

Department of Prosthodontics, New York University College of Dentistry,  
New York, USA



Correspondence to: Eric Van Dooren DDS

Tavernierkaai, 2, 2000 Antwerpen, Belgium; Tel: +32-3-2380835; E-mail: vandoorendent@skynet.be

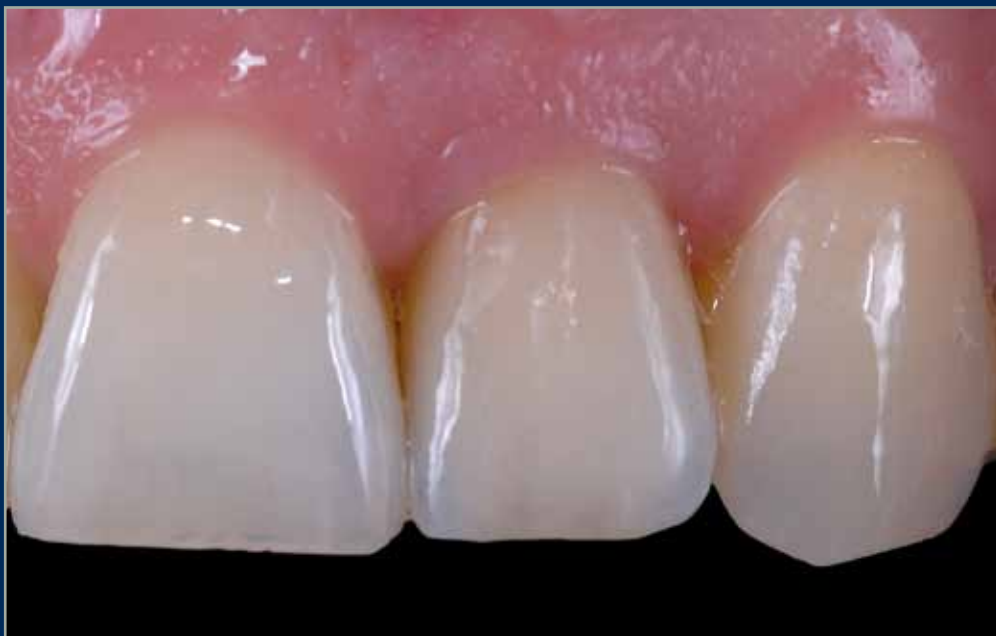

## Abstract

The objective of this narrative overview is to discuss several in vitro and in vivo studies regarding the performance of one-piece zirconia implants in combination with the description of two clinical

scenarios where zirconia implant prototypes were utilized with emphasis on the possible scientific and clinical concerns that may affect the functional, biological and esthetic long term outcomes.

*(Eur J Esthet Dent 2012;7:xxx-xxx)*





### Introduction

Despite the recognized biocompatibility of titanium alloy surface protective oxide layers, metallic ion release has raised concerns over the last decade.<sup>1</sup> Increased concentration of titanium has been observed in tissues close to the implant surfaces<sup>2</sup> and also in regional lymph nodes.<sup>3</sup> Although the clinical relevance of these observations is uncertain, demand for metal-free treatments is increasing in dental practice.

Due to its high flexural strength (900-1,200 MPa), favorable fracture toughness (KIC 7 to 10 MPam<sup>-1</sup>), and satisfactory Young's modulus (210 GPa),<sup>4</sup> Zirconia (yttria-stabilized tetragonal zirconia polycrystal- Y-TZP) has been proposed as an alternative to metallic alloys. Biologically, zirconia has been shown in both *in vitro* and *in vivo* experiments to exhibit desirable osseointegration, cell metabolism, and soft tissue response.<sup>5,6</sup> In addition, zirconia implant human histology has demonstrated morphology suggestive of lamina dura and, thereby, the potential for increased quality of osseointegration.<sup>6</sup>

In orthopedics, zirconia has been extensively utilized as a material for femoral ball-heads in total hip replacements since its introduction in the 1980s.<sup>7</sup> In dentistry, zirconia has been used for cores and frameworks in all-ceramic restorations, as well as for ceramic abutments in dental implant prostheses.<sup>8</sup> Although ceramic abutments associated with all-ceramic crowns have been shown to be an excellent treatment in critical esthetic situations, the presence of an abutment fixture junction has raised concerns.<sup>9</sup> Thus, the utilization of a one-

piece zirconia implant might be an option to fulfill the esthetic and functional requirements in dental implant therapy, particularly when thin biotype tissue is present.

It is important to note that although several zirconia implant systems are available on the market (examples of ceramic implants are: White Sky implant system (Bredent Medical & Co); Cera-root® one-piece zirconia implant system (Ceraroot®); Sigma implants (Incermed SA) zit-z implants (Ziterion); Z-Look3 (Z-systems®)), rigorous prospective and retrospective clinical trials have not been reported. Moreover, several articles available in the literature present zirconia implant prototypes (not available in the market), which make its clinical application controversial.

This article discusses *in vitro* and *in vivo* studies using zirconia implants and presents two clinical scenarios in which zirconia prototype implants were utilized as the treatment of choice, illustrating their potential to enhance the final long-term clinical esthetic outcome.

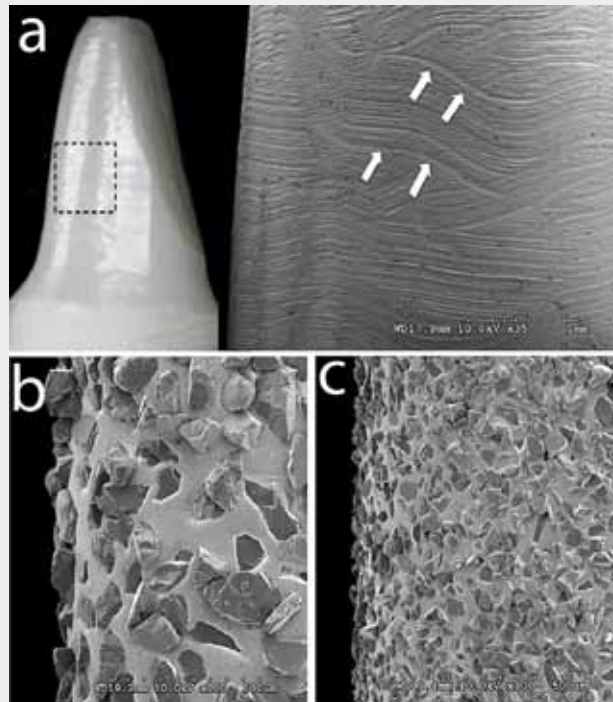
### Mechanical behavior: *in vitro* investigations

Unlike orthopedic devices, zirconia implants frequently need to be modified after surgical placement to achieve optimal crown contours. This preparation is performed using coarse and fine grain diamond burs (Fig 1). Abrasive surface damage has been implicated in decreasing the clinical life expectancy of dental ceramics as a result of slow crack growth.<sup>10</sup> The assumptions were obtained from mechanical tests per-



formed on 0.5 to 1.50 mm thick glass or ceramic-layered structures. Therefore, abrasive surface damage becomes relevant for cores and veneers on partial or full crown restorations and fixed dental prostheses. This deleterious effect on ceramics worsens when water is present during loading, a phenomenon known as hydraulic pumping,<sup>10</sup> where flaws on the ceramic surfaces created by grinding or wear entraps water (or saliva). Under fatigue (or mastication forces), tension sites at the crack tips are generated because of the presence of fluid forced into these flaws, resulting in faster crack growth. Considering the fact that the final crown is always cemented on prepared zirconia implants, it is reasonable to expect that the water pumping phenomenon will not have any effect on the long term survival of zirconia implants although damage might be incurred on the cemented restoration.

*In vitro* investigations evaluating the mechanical performance of zirconia oral implants are available in the literature<sup>11–14</sup>. These studies also address the surface damage created during crown preparation. Three of the investigations evaluated fatigue response of similar zirconia implants<sup>11–13</sup> and one study investigated the impact fracture resistance of zirconia implants in comparison to two titanium-implant-abutment systems<sup>12</sup>. This study found no difference in fracture energy between two titanium-abutment systems (titanium and zirconia abutment) and one-piece zirconia implants placed in foam blocks. In all instances the foam block fractured, suggesting that when titanium or ceramic fixtures are osseointegrated, facial trauma is likely to lead to alveolar fracture, consequently leaving



**Fig 1** Image “1a” shows digital picture and scanning electron microscopic (SEM) picture of the head of a one-piece zirconia implant (Nobel Biocare) after full crown preparation. The black dotted box represents the SEM area. Note the white arrows pointing to the scratches produced by coarse bur “b”. The overall preparation shows prominent marks produced even after utilization of fine grain diamond bur “c”.

the implant undamaged.<sup>12</sup> Also, the differences in fracture mechanism suggest that a patient receiving a traumatic injury that would result in fracture of a natural tooth, might not fracture an osseointegrated titanium or zirconia implant. The same research team<sup>11</sup> evaluated fatigue reliability of **as-received** compared to zirconia implants with **coronal** portions prepared by diamond burs. All specimens were step-stress fatigued until failure



or survival. The authors concluded that crown preparation does not influence the reliability of the one-piece zirconia ceramic implant, and that fatigue has little influence on the survival of these implants at loads under 600 N. Another research group<sup>13</sup> evaluated the fracture strength of one-piece zirconia implants using a universal testing machine after artificial loading in the chewing simulator. Fifteen different groups (4 titanium implant groups and 11 zirconia implant groups with different pretreatments) were investigated. Seven of the 72 artificially loaded implant samples failed in the chewing simulator. Zirconia implant fracture occurred at 725 to 850 N when the implants were not prepared, and at 539 to 607 N when prepared. In contrast to Silva et al,<sup>11</sup> this study concluded that implant preparation had a negative influence on the zirconia implant fracture strength. It is important to recognize that the zirconia implants in both studies<sup>11,13</sup> received full crown preparations following guidelines for preparation of anterior teeth and the failure loads were significantly higher than the maximum biting force in the anterior region (206 N)<sup>15</sup>. It was concluded that the zirconia implants should withstand intraoral loading conditions in the esthetic zone.

### Low temperature degradation of zirconia

It is known that zirconia undergoes low-temperature degradation via surface transformation from the tetragonal to monoclinic phase in the presence of water or water vapor.<sup>16</sup> This ageing phenomenon was considered to be very

limited under *in vivo* conditions until Chevalier<sup>17,18</sup> reported early failures of 400 femoral heads in 2001. The failures were associated with a change in the processing technique and accelerated ageing of two batches of Prozyr femoral heads.

The mechanism of the ageing process and its deleterious effect on the performance of zirconia involves an increase of surface roughness and subsequent microcracking.<sup>17,18</sup> These two phenomena combined might lead to pullout of the zirconia grains. Therefore, the biological interaction of these small particles with immune system cells becomes critical.<sup>18</sup> These observations from Chevalier's group were based on the fact that the zirconia head is in direct contact with an antagonist part of the prosthesis, therefore an increase in wear rate can be exacerbated by the consequences of ageing.

Reports in the dental literature are limited and inconclusive regarding the possible implications of the accelerated ageing phenomenon of zirconia on the mechanical properties and biological response for crowns, fixed partial dentures, abutments, and implants. From a clinical perspective, the crown preparation performed on zirconia implants may lead to an accelerated ageing phenomenon as a result of the damage caused by the burs. However, one cannot expect wear directly on the zirconia implants after crown preparation, since crowns are cemented on the preparations. Conversely, depending on the type of surface treatment performed on the zirconia to promote better osseointegration, the accelerated ageing phenomenon might become an important



factor affecting the biological response. The clinical relevance of the accelerated aging phenomenon on one-piece zirconia implants is not yet clear and no failures of these implants associated with accelerated aging phenomenon have been reported. All these assumptions related to the accelerated ageing process of zirconia point to the need for further investigations in the fields of orthopedics and dentistry.

## Radioactivity concerns

Zirconia is well known for promoting positive tissue responses. However, concerns regarding the presence of radioactive components during its fabrication (zirconia powder) have been discussed.<sup>19</sup> The radioactive exposure is caused by impurities in the zirconia manufacturing process. Although, *in vitro* carcinogenicity and mutagenicity tests on zirconia have shown negative results,<sup>20,21</sup> ceramic manufacturers are encouraged to control the purification process of zirconia<sup>22</sup> to avoid any possible radioactive impurity in one-piece ceramic implants. Radiation protection while handling zircon sands is frequently utilized for the safety of professionals in this field.

## *In vivo* investigations

This section presents some of the studies on zirconia implants utilized in animal models, mainly investigating the effects of surface modifications on bone-to-implant contact (BIC) response. Scarano et al<sup>23</sup> investigated the bone response of

zirconia implants in the tibiae of rabbits and reported 68% BIC. Akagawa et al<sup>24</sup> evaluated the degree of BIC of loaded and nonloaded zirconia implants placed in the maxillae using the dog model. There was a slightly higher BIC found for the nonloaded implants (82%) compared to the loaded ones (70%). There was also loss of crestal bone evident around the loaded implants. Another study performed by the same group<sup>25</sup> revealed direct bone apposition (> 50% BIC) after two years in the different implant investigation groups.

Sennerby et al<sup>26</sup> performed a comparison between different zirconia implant surfaces. One particular modified zirconia implant surface showed resistance to torque forces similar to oxidized titanium implants. Considering implant placement location using a rabbit model for the study<sup>26</sup>, two tested modified zirconia implant surfaces showed a BIC in the femur of 60 to 70% compared to ~ 78% for titanium oxide implants and of approximately 20 to 30% in the tibia compared to ~ 25% for titanium oxide implants. Hofmann et al<sup>27</sup> compared bone apposition around 4 zirconia implants and 4 surface-modified titanium implants. The degree of BIC (zirconia 2 weeks: ~ 55%, titanium 2 weeks: ~ 47%; zirconia 4 weeks: ~ 71%, titanium 4 weeks: ~ 80%) was similar on all implants during an early healing phase. Deprich et al<sup>28</sup> did not find statistically significant differences between acid-etched zirconia and titanium implants after implants were inserted in tibiae of mini pigs. Lee et al<sup>29</sup> evaluated nanotechnology-modified zirconia implants placed in rabbits. Three different zirconia implant groups (two with a nanotech-





nology surface modification using calcium phosphate) were compared with titanium oxide implants. The titanium implants demonstrated a BIC of 77% after 3 weeks of healing, being significantly different to the nanomodified zirconia surfaces. The unmodified zirconia surface had a BIC of 71% after 3 weeks. Kohal et al<sup>30</sup> presented the biomechanical and histological behavior of zirconia implants with no statistically significant different BIC values for rough titanium and zirconia surfaces. After 14 days of healing, rough titanium showed a BIC of 36% and 45%. For rough zirconia after 28 days the BIC amounted to 45% for titanium and 59% for zirconia. Rocchietta et al<sup>31</sup> investigated a topographically modified zirconia using oxidized titanium implants as a control group. The removal torque values for the different zirconia implants were not statistically significant different ranging from 29 N/cm<sup>2</sup> (not HA coated) to 37 N/cm<sup>2</sup> (sputter coated). The histological analysis revealed values for the BIC from 28% (not HA coated) to 58% (oxidized titanium) with no significant differences (95% confidence intervals).

It can be concluded that the above-mentioned studies comparing zirconia to titanium implants showed that the bone-to-implant contact was similar for both materials, demonstrating that zirconia can potentially be utilized as a material for dental implants.

## Clinical evaluations

While more definitive answers are not yet available regarding the mechanical and biological performance of zirconia implants, including the effect of accelerated aging phenomena, some clinical studies have already been performed using these implants. For instance, in two of these studies, Oliva et al presented one- and five-year follow-ups of ceramic implants placed in patients with ages ranging from 18 to 80.<sup>32,33</sup> The authors also compared implants with different surface roughnesses and designs. The implants were placed in anterior and posterior regions following standard surgical procedures. Oliva's group presented an overall success rate of 98% and 95% after 1 and 5 years respectively.<sup>32,33</sup> The success rate of the acid-etched implant group (97.60%) was significantly higher than coated (93.57%) and uncoated implants (92.77%).

Lambrich et al<sup>34</sup> conducted a study in which 361 implants (127 zirconia and 234 titanium) in 124 patients were placed and followed for an observation period of 21.4 months. The survival rate of the titanium implants were 98% in the maxilla and 97% in the mandible, while the zirconia implants showed a survival rate of 84% in the maxilla and 98% in the mandible. The failures (10 implants in the maxilla and one implant in the mandible) occurred during the healing period up to the first 6 months. No implant fracture was reported.

There is clearly a need for well-designed, long-term, prospective studies concerning one-piece zirconia dental implants that include peri-implant bone remodeling/loss data.



## Success of zirconia implants based on design and clinical guidelines

The success of zirconia implants is dependent on proper understanding of implant design and surface characteristics, patient selection and adherence to proper surgical guidelines. When working in the esthetic zone, clinicians must preserve the natural components of the smile. Tooth morphology, soft tissue architecture, lip support and smile design need to be optimal for the final esthetic outcome. New advancements in dental technology have created treatments never possible in the past, especially for dental implant therapy. However, caution is advised to avoid creating unrealistic expectations based on case reports in the literature and presentations at dental meetings. Inadequate diagnosis and treatment planning could lead to **dissatisfying** and unacceptable esthetic results, disappointing both clinician and patient.

The success of implant dentistry in critical esthetic zones depends on the combination of prosthetic and surgical soft tissue managements. Minor surgical errors could create major soft tissue discrepancies. Moreover, inadequate utilization of prosthetic components and restorative materials might lead to disappointing results in the esthetic zone, and subsequent failure of the final esthetic result.

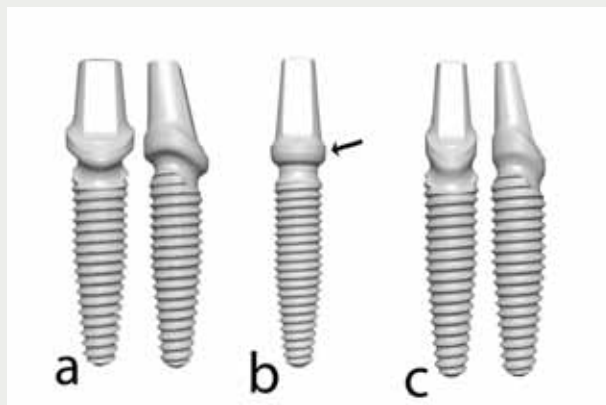
The creation of ideal and stable soft and hard tissue contours around implant-supported restorations is still a challenge. Zirconia implants were introduced to the market to potentially enhance the oral implant armamentarium,

particularly for highly crucial esthetic situations.

New prototypes of one-piece zirconia implants were designed in collaboration with Nobel Biocare in the beginning of 2006. The main idea behind this project was to create an implant design with a concave transmucosal region and evaluate the long-term soft tissue stability after implant placement. Until now, scientific and histological evidence showing fibrous attachment on implant or abutment surfaces is limited. The long-term soft tissue stability in the transmucosal zone relies on the thickness of the connective tissue fibers, referred to as the “O-ring effect”.<sup>35,36</sup>

Therefore, the soft tissue thickness could potentially be improved utilizing a concave transmucosal design between the head and first thread of the zirconia implant. Another option could be the combination of a concave transmucosal form with a screw-retained zirconia abutment. However this screw-retained system presents a potential design limitation as the thickness of the zirconia abutment is reduced significantly at the implant/screw/abutment interface, potentially leading to mechanical failures. Therefore, the one-piece ceramic implant seems to be the optimal design.





**Fig 2** One piece ceramic implant prototypes. **(a)** shows a prototype with a circular transmucosal region (black arrow). **(b)** represents front and side views of a zirconia central incisor implant. **(c)** shows front and side view of a lateral zirconia implant. Note in **(b)** and **(c)** the scalloped transmucosal regions compared to **(a)**. **(b)** and **(c)** also show the 15 degree inclination of the axial walls of the head of the implants to facilitate prosthetic procedures.

### Zirconia implant prototypes

The first implant prototypes presented a straighter configuration with symmetrical form (Fig 2a). The second prototype (Figure 2b and 2c) was developed after 1 year with an asymmetrical design. The circumferential concave transmucosal groove of the first prototype was modified into a scalloped transmucosal groove, simulating the silhouette of the natural tooth surrounding bone. The prosthetic coronal part of the implant (head) presented a 15 degree angulation with a specific prosthetic diameter, where a narrower prosthetic platform was used for lateral incisors and wider prosthetic platform for central incisors and canines (Fig 2b and 2c). The scalloped prototype implants were placed and evaluated in several patients with

reported long-term success (Van Dooren E, Rompen E and Touati B, unpublished data) and will be presented in the clinical cases descriptions.

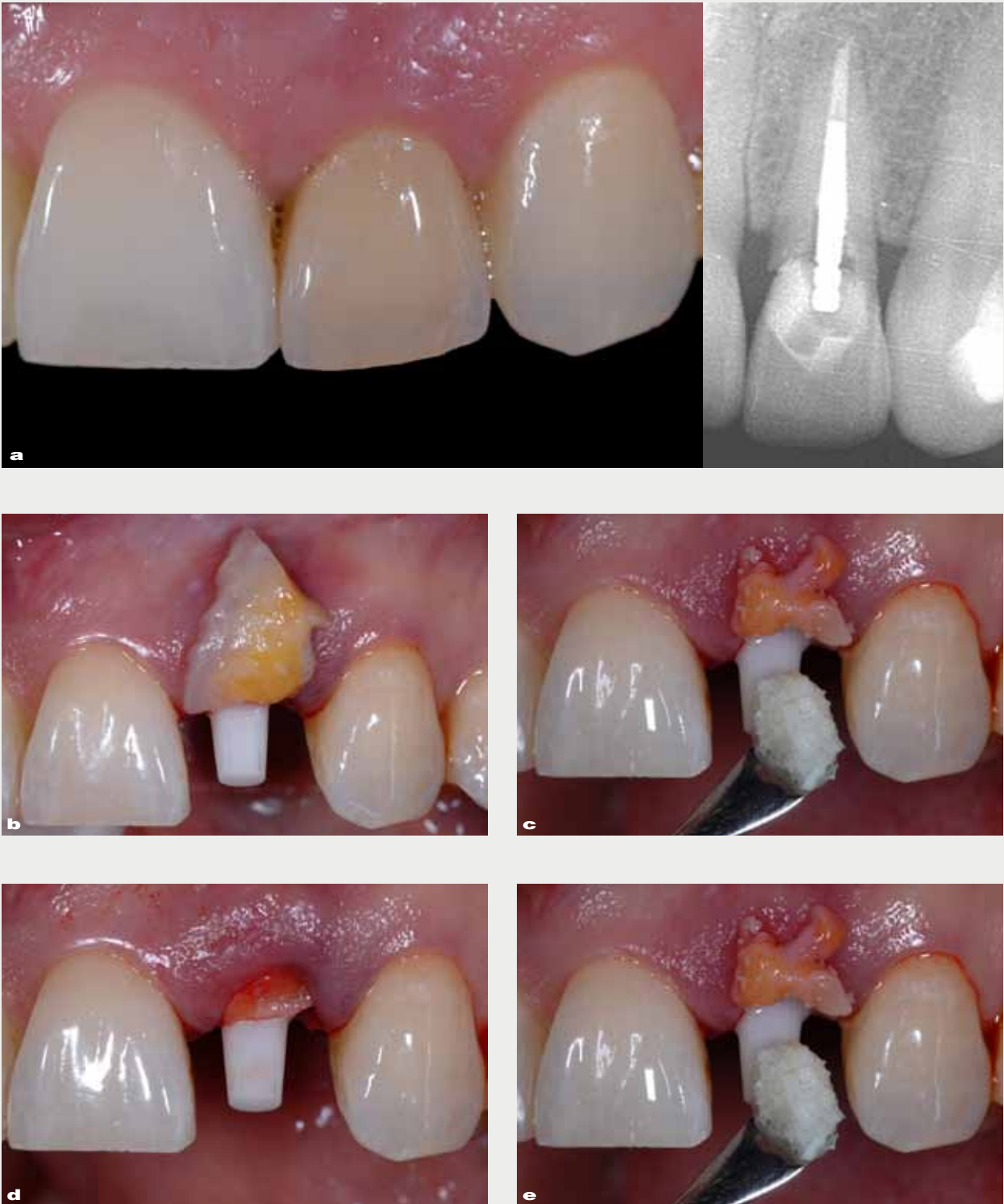
### Surgical and prosthetic considerations

This section addresses clinical aspects related to zirconia implant design and clinical concerns that may influence the clinical success of zirconia implant therapy. Two clinical scenarios were selected and presented in this article in order to explain the concept and surgical protocol associated with the prosthetic rehabilitation when zirconia implants were the treatment therapy of choice.

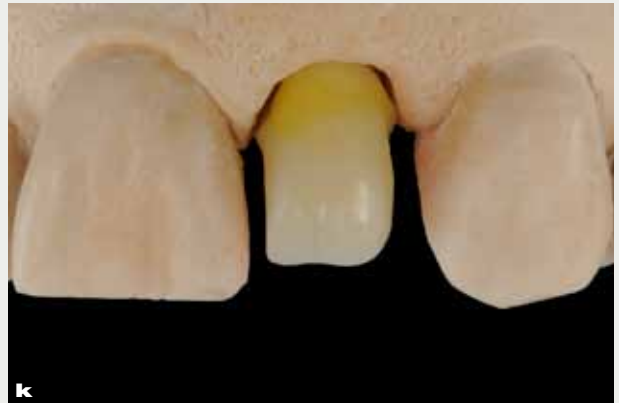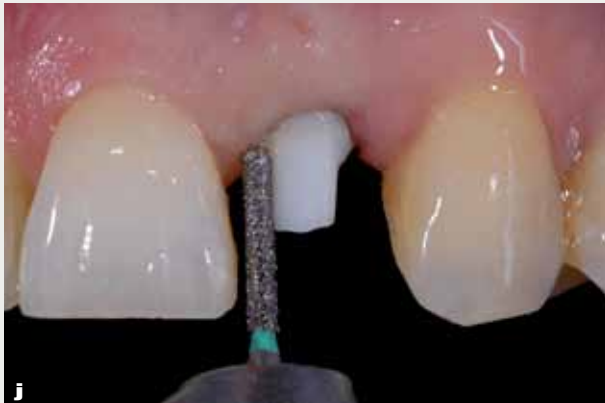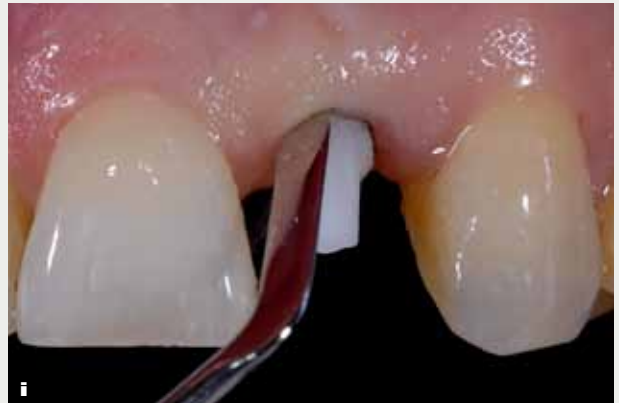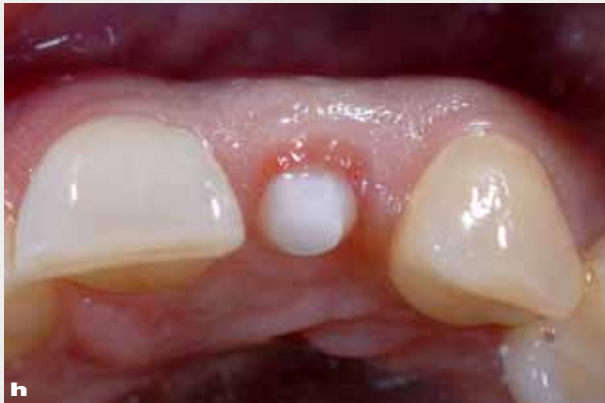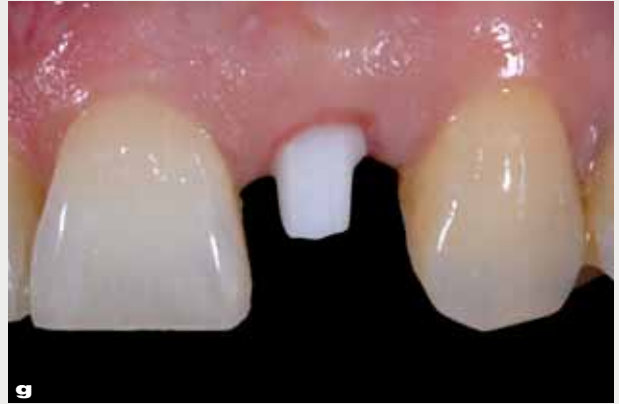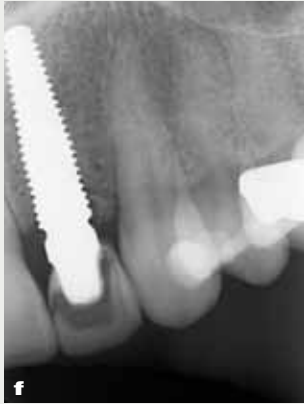#### Surgical considerations (case report 1)

A 30-year-old female patient presented with a fractured left lateral incisor (Fig 3a). Microscopic evaluation revealed a crack in the labial aspect of the root. The fractured coronal part was bonded provisionally to the root with a metal post. Radiographically, the supracrestal fracture line was visible (Fig 3a). No bleeding was present during probing and the labial bone was intact. The patient exhibited a very thin gingival biotype<sup>35,36</sup> and a moderate to high smile line,<sup>37</sup> with full exposure of the dento-gingival complex and surrounding soft tissues.

The patient was willing to undergo comprehensive treatment in order to achieve her esthetic goals, however she was reluctant to proceed unless minimally invasive surgery was performed. A treatment plan was proposed, involving

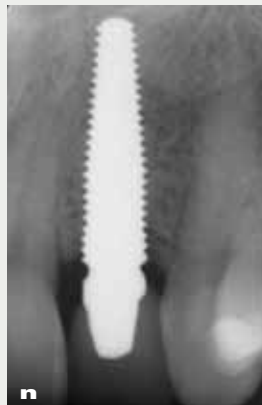
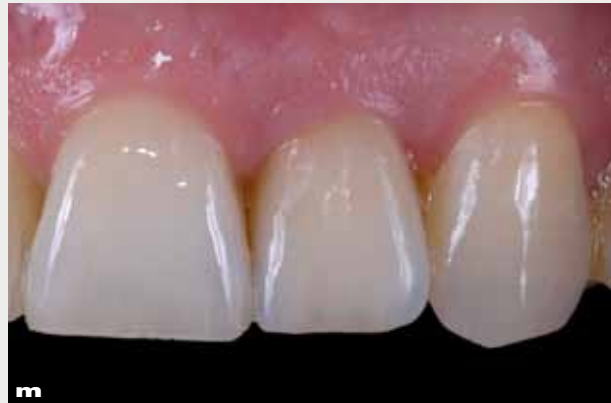
**Fig 3**



extraction of the lateral incisor followed by the immediate zirconia implant placement and temporization for subsequent prosthetic replacement.

A nontraumatic extraction<sup>38</sup> was performed using periostomes to preserve the facial bone contour. Care was taken to completely debride the socket with



a curette and remove the periodontal ligament before implant placement. A one-piece zirconia implant (Nobel Biocare) with a “narrow prosthetic diameter” (Fig 2c) was placed in the extraction socket. The implant was secured by engaging the palatal bone of the extraction socket to obtain primary stabilization and avoid contact of the facial bone plate, allowing a 2 mm gap for the grafting procedure (Bio-Oss, Geistlich).<sup>39</sup> Subsequently, a connective tissue graft was harvested from the tuberosity region and secured into a split thickness facial pouch with a sulcular approach (Fig 3b–3d). Sutures (Fig 3e) were placed and care was taken to have a passive, tension-free fit of the connective tissue graft

into the facial pouch. The connective tissue graft allowed for partial compensation of the crestal bone resorption that commonly occurs after extraction.<sup>40, 41</sup>

With this graft approach, thick connective tissue could be formed around the transmucosal zone where the zirconia implant prototype presents the concave design. The prosthetic component of the implant with the facial-lingual angulation of 15 degrees allowed immediate provisionalization (Fig 3e).

The post-op radiograph (Fig 3f) shows the position of the most coronal scalloped interthread. With conventional implant systems, fixtures are frequently placed excessively deep with the potential to induce bone resorption.



With the utilization of the prototype described in this article, less interdental bone resorption might be observed due to the more coronal position of the interdental threads.

After 3 months of healing, the marginal soft tissue form was excellent. This might be a result of the combination of connective tissue grafting and the implant transmucosal concave profile, allowing for soft tissue thickness and stability in the critical zone. Compared to baseline (Fig 3a), papilla height and volume decreased very slightly initially, due to surgical trauma. At this stage, initial healing was complete and osseointegration achieved.

The provisional crown was removed, and preparation was performed by establishing adequate marginal soft tissue contours and a zenith position and retraction cord were inserted (Figure 3g–3j) for final impressioning. A Procera alumina coping (Nobel Biocare) was fabricated (double scanning technique) (Fig 3k) and the porcelain veneer applied (Figure 3l) (Nobel Rondo, Nobel Biocare). Care was taken to provide the optimal prosthetic gingival support allowing for optimal long-term soft tissue stability. At the 3-year recall, the soft tissue levels remained stable (Fig 3m). The 3-year post-op radiograph shows only minor changes of interdental bone levels (Fig 3n).

The impact of the proper design of the transmucosal component in the soft tissue health and stability was evident in the clinical scenario described above. The combination of concave zirconia implant design and connective tissue graft seems to play a significant role in the long term esthetic and functional outcome.

### Prosthetic considerations (case report 2)

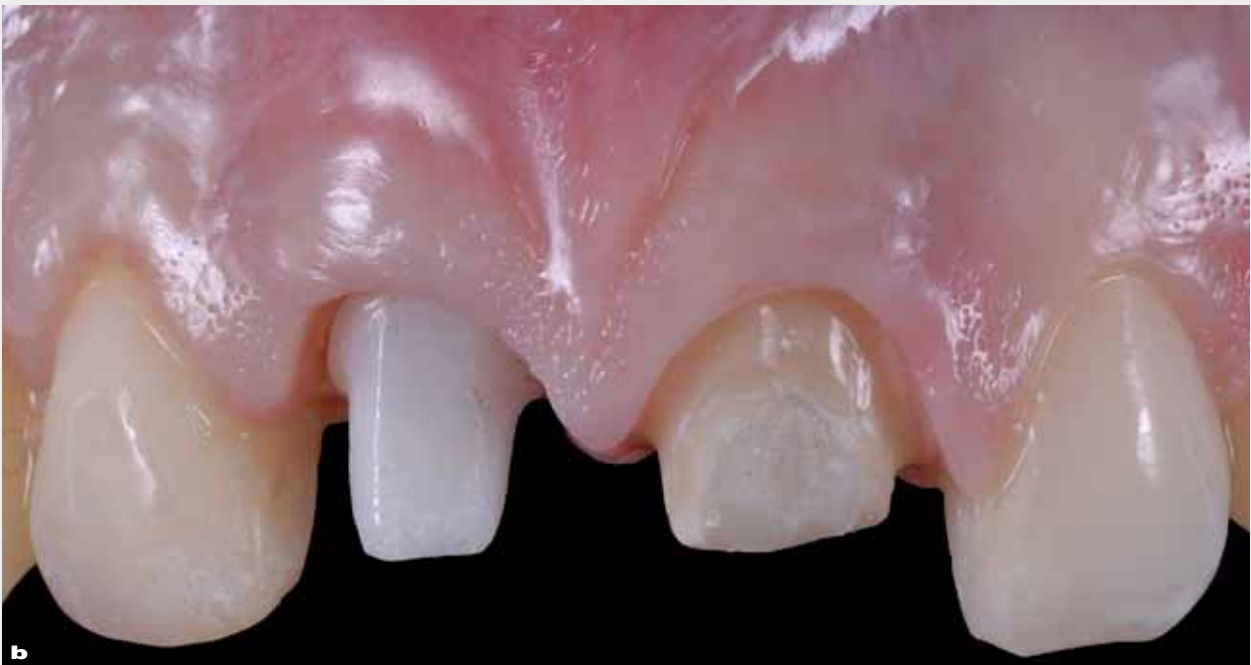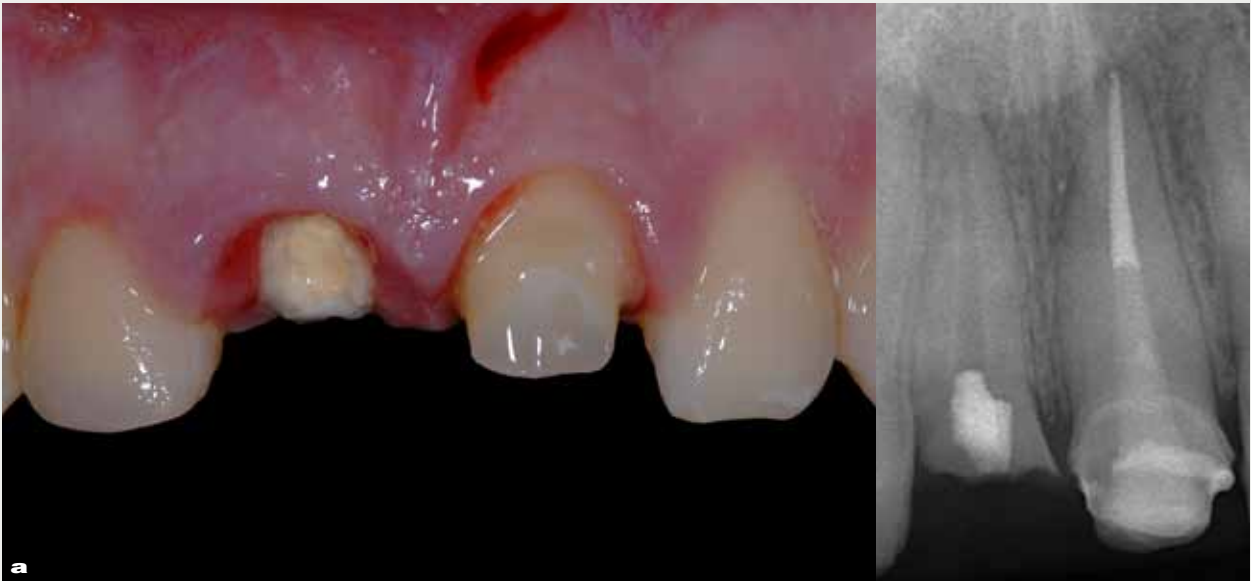A 28-year-old male patient presented with a severe esthetic problem associated with trauma of the anterior dentition (Fig 4a). The left central incisor was endodontically treated and restored with a fiber post, followed by a composite build-up. The right central incisor exhibited a vertical fracture line, necessitating extraction. Neither bleeding nor facial bone loss was detectable by probing. A two-unit provisional bridge was fabricated prior to extraction and implant placement.

A one-piece zirconia implant (Fig 4b) was placed with the same surgical protocol as described in the prior clinical example. For this clinical scenario, the implant design with a wider prosthetic diameter was used (Fig 2b). This implant configuration allowed for better anatomical form of the final crown to match the dimensions of a central incisor.

However, even with these advanced asymmetrical designs, utilization of one-piece implant systems requires a more specific understanding of the prosthetic rehabilitation. In general, two-piece implant systems allow individualized transmucosal designs, whereas one-piece implant systems have limitations. It is important that both prosthodontist and lab technician understand the impact of soft tissue contouring and prosthetic support on the biology for the stability of the soft tissue.

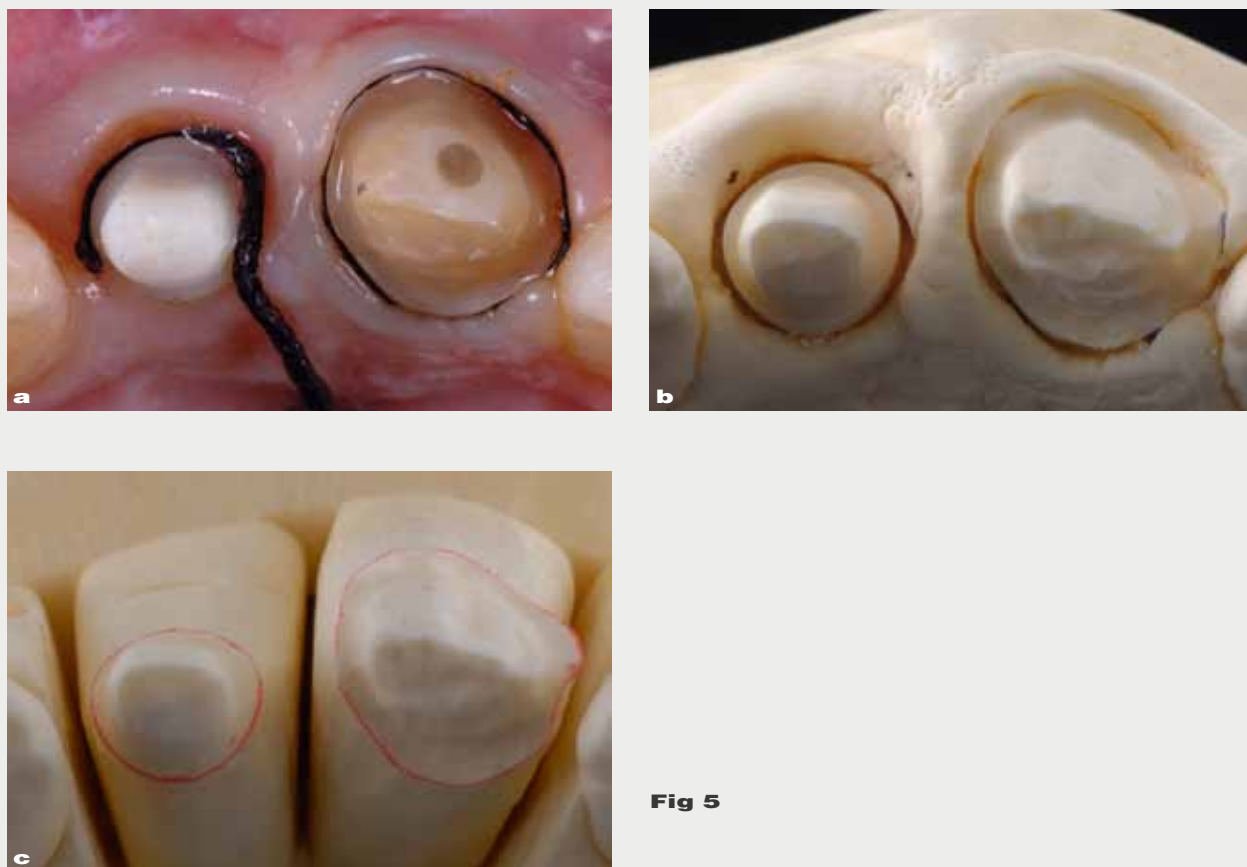
Although provisionalization and relining could promote soft tissue architecture during the temporization step, it becomes imperative that the technician optimizes the soft tissue contour





**Fig 4**



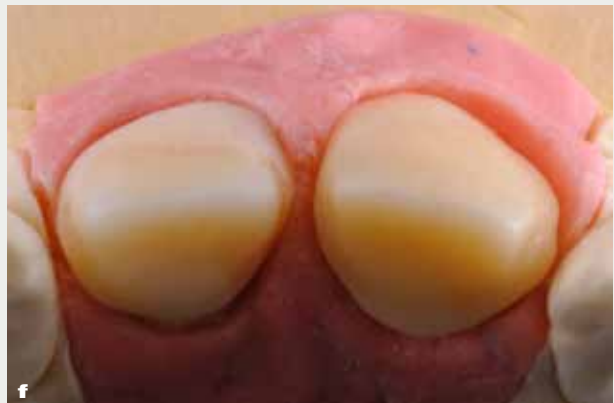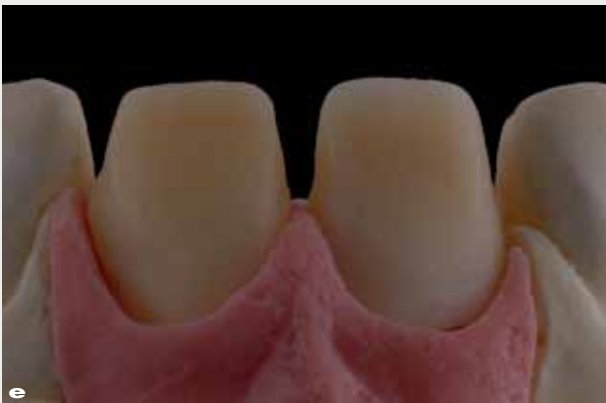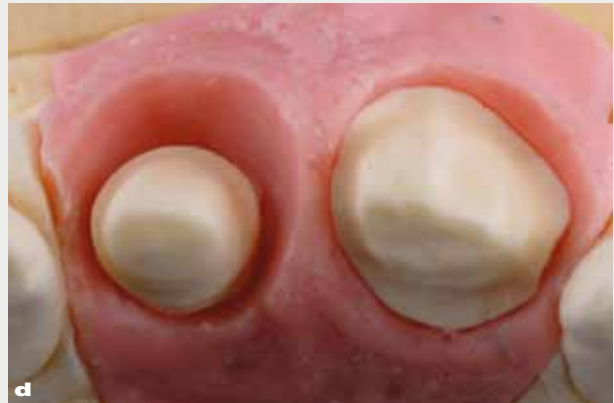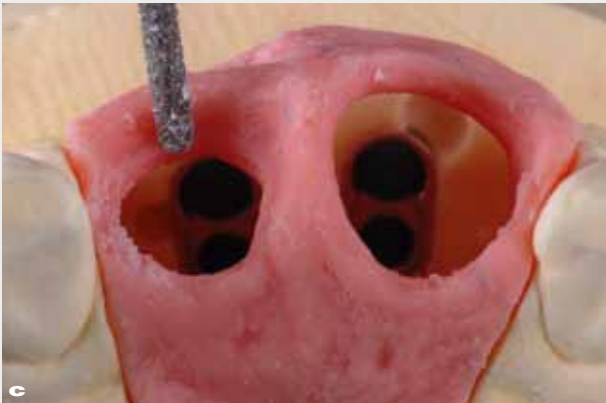
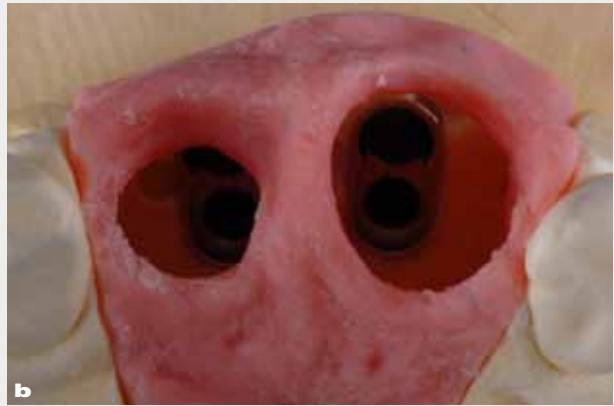


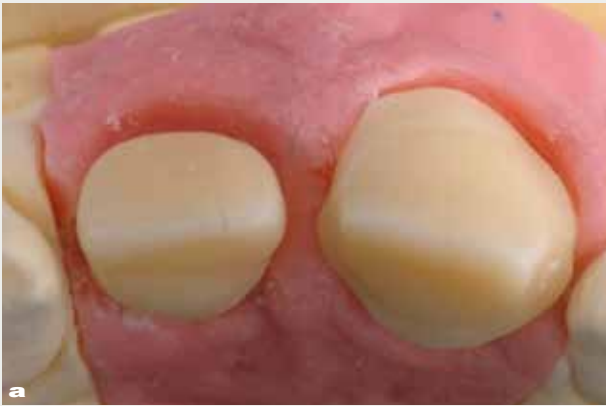**Fig 5**

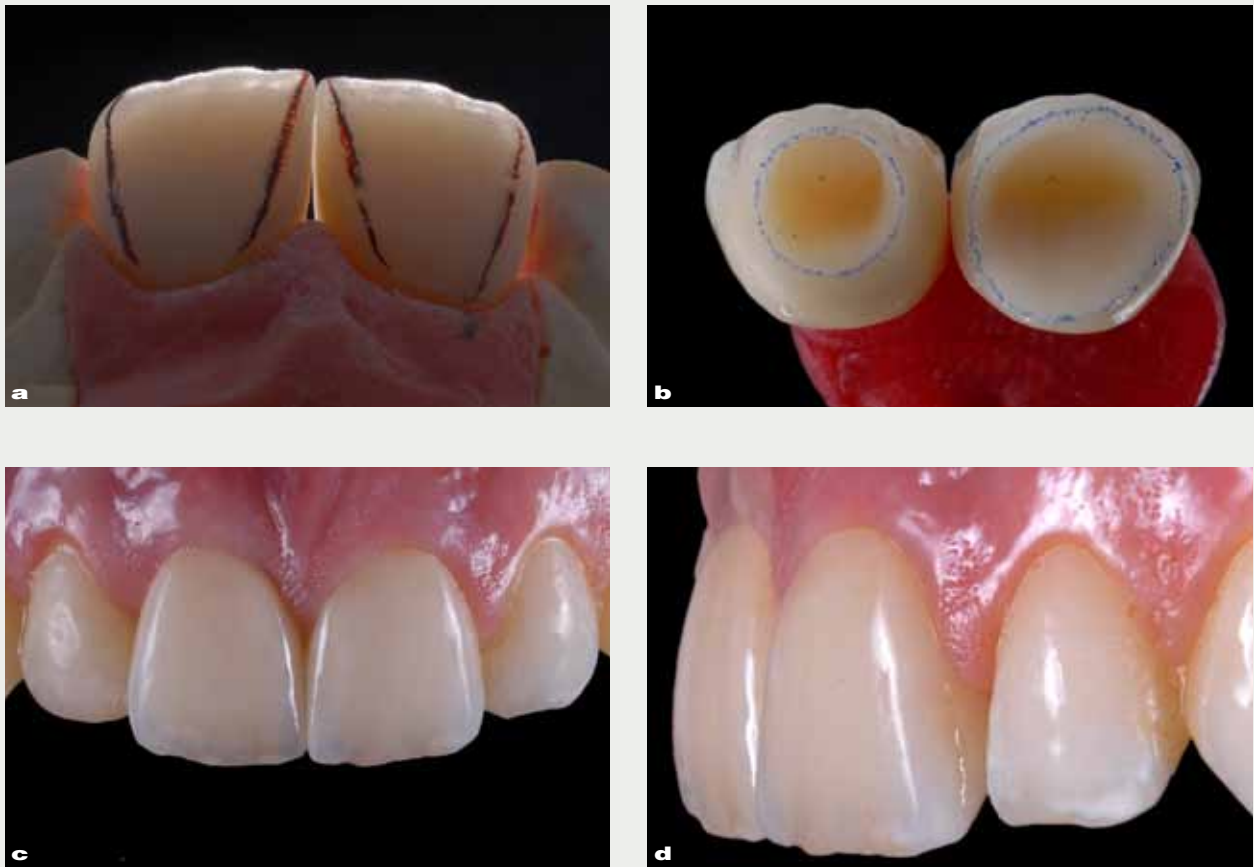
on the master cast. For this procedure, two master casts are needed: a first die cast with silicone soft tissue mask and a solid cast to check the contact points. The master cast represents a perfect replica of the existing clinical situation. For the case presented in this section, there is a clear discrepancy between the diameter of the implant when compared to the contralateral natural tooth (Figure 5a–5c) that may result in a deeper cement margin when compared to a two-piece implant system with custom transmucosal abutment designs. From this point, the objective is to mimic the preparation configuration of a natural

tooth, with the abutment margin being positioned slightly within the gingival sulcus. With a one-piece implant system the crown emerges in the last 25 to 30% of the transmucosal space to allow for proper prosthetic soft tissue support. Although the provisional bridge was re-lined in this clinical case, the technician needed to optimize the peri-implant soft tissue contour on the master cast.

Figure 6a to 6f illustrates the removal of the dies and the reshaping of the soft tissue mask with a diamond bur mimicking the gingival emergence angle, contour and zenith position of the contralateral tooth. Two Procera Alumina copings



**Fig 6**

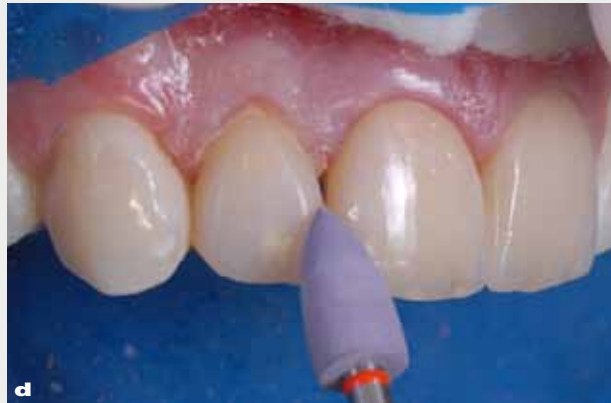
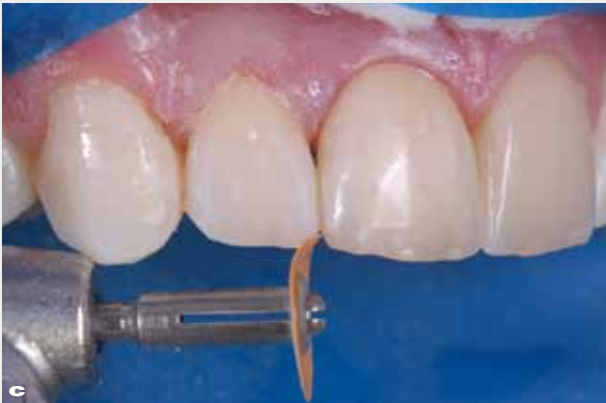
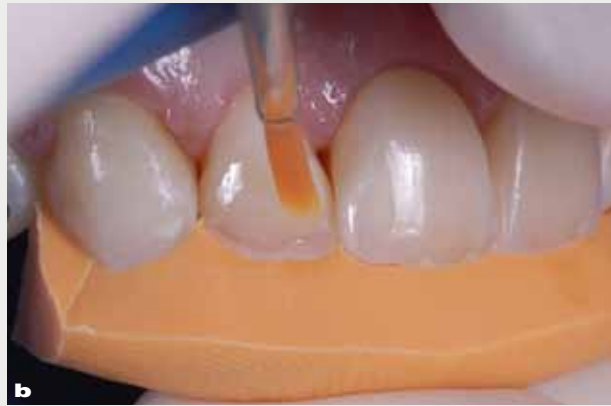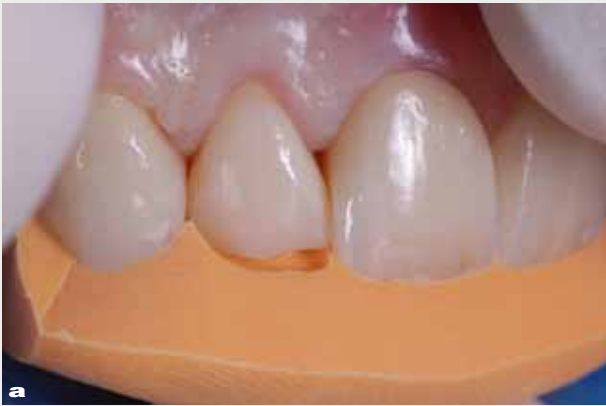**Fig 7**

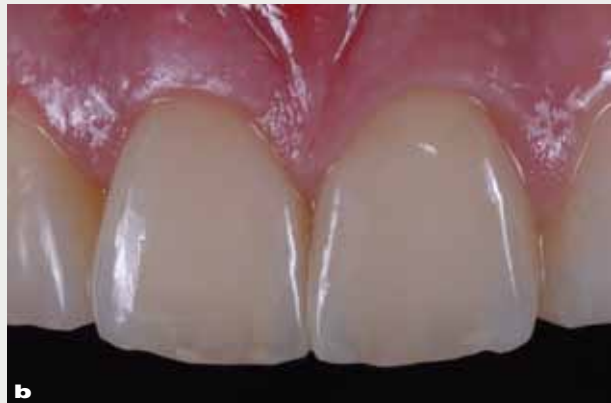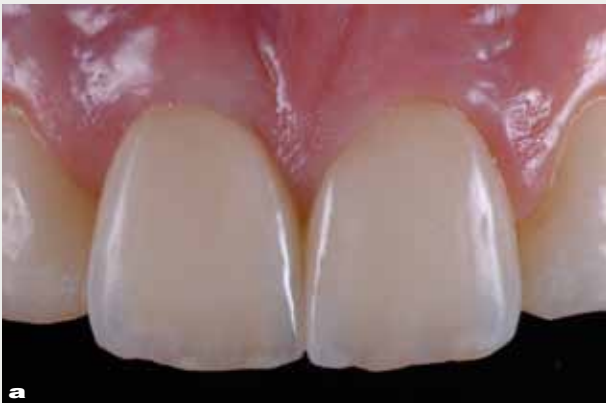(Nobel Biocare) were fabricated. The dental technician applied an additional volume of marginal ceramic (Nobel Rondo, Nobel Biocare) on the facial aspect of the coping (Figure 6e and 6f) in order to mimic the contour and shade of the natural tooth.

The marginal ceramic is believed to be stable after processing due to its high firing temperature and seems to have minimal shrinkage during multiple firings throughout the layering process.

The subgingival contour and the emergence angle of the implant crown is completely different from the natural tooth. Care must be taken to avoid excessive pressure on the transmucosal mask tissue. A slightly concave subgingival contour or negative submergence profile is essential to minimize pressure and to leave the space for connective tissue in the critical zone (Fig 7a–7d). Since it is virtually impossible to exactly duplicate the profile and soft tissue contour on the

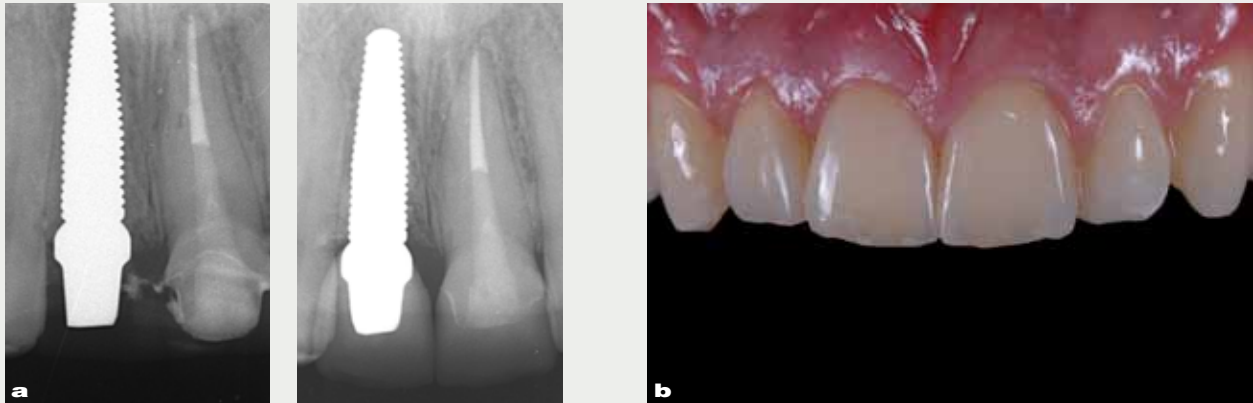

**Fig 8**



**Fig 9**





**Fig 10**

zirconia implant restoration compared to the contralateral natural tooth, and since there is a lack of papilla thickness and height on the distal aspect of most of implant restorations, clinicians need to rely on the dental technician's skills **to obtain the optimal esthetics desired.**

The greatest challenge in creating implant-supported restorations in the esthetic zone involves creating the ideal position and shape of a natural tooth. Any excessive gingival pressure of the prosthetic components might lead to apical tissue migration or recession. Therefore, for anterior implant restorations, the dental technician is advised to work with optical illusion to achieve the best esthetic result (Fig 7a–7d) without compromising the soft tissue stability.

After finalizing the crowns, the right lateral incisor (Figure 8a–8d) was restored with a composite restoration to match the esthetics of the anterior crowns (courtesy of Dr Claudio Pinho, Brazilia, DF, Brazil). The composite was fabricated according to a wax-up and silicone index fabricated in the laboratory with the final crowns *in situ*.

At 6-months post-op (Figure 9a), the soft tissue appearance was satisfactory, although a lack of papilla height and especially of papilla volume at the distal site of the implant-supported restoration was observed. The lack of volume resulted in a slight shadow at the mesial and distal angle of the crown. However, the clinical outcome improved substantially at 4-year post-op showing a clear gain in papilla height and volume (distal papilla) of the implant-supported crown, resulting in a better match of the restored natural tooth (Figure 9b). The 4-year post-operative radiograph (Figure 10a) exhibited stable bone levels. The authors speculate that the soft tissue thickness associated with the O-ring effect of the connective tissue fibers might have resulted in the long-term bone level stability observed in Figure 9a and 9b. The radiograph in Figure 10a reveals a minor change in bone levels into the interdental concavity. The authors speculate that soft tissue maturation may occur over a period of time of 2 years and that phenomenon is the key for long-term esthetic out-



come of zirconia implant restorations (Fig 10b). More subjects for long-term observations are needed to confirm these observations.

## Conclusion

One-piece zirconia implants have shown to be very robust after mechanical testing evaluations. The issues related to phase transformation of zirconia are still not clear and more investigations are needed. *In vivo* studies have showed very positive bone tissue and soft tissue response to the zirconia surface. More *in vitro* and *in vivo* research is needed to increase clinicians' confidence in using

zirconia implants. The clinical cases presented in this article demonstrate long-term soft tissue stability combined with very high esthetic results. Increasing or improving the soft tissue thickness and quality and the combination of connective tissue graft and precise prosthetic design seems to promote optimal functional and esthetic results when one-piece zirconia implants are used.

## Acknowledgments

The authors thank the Department of Prosthodontics and Department of Biomaterials and Biomimetics at New York University for the outstanding research in ceramics under the leadership and guidance from Drs Van P. Thompson and Elizabeth Dianne Rekow.

## References

- Smith DC, Lugowski S, McHugh A, Deporter D, Watson PA, Chipman M. Systemic metal ion levels in dental implant patients. *Int J Oral Maxillofac Implants* 1997;12:828–834.
- Bianco PD, Ducheyne P, Cuckler JM. Local accumulation of titanium released from a titanium implant in the absence of wear. *J Biomed Mater Res* 1996;31:227–234.
- Weingart D, Steinemann S, Schilli W, Strub JR, Hellerich U, Assenmacher J, et al. Titanium deposition in regional lymph nodes after insertion of titanium screw implants in maxillofacial region. *Int J Oral Maxillofac Surg* 1994;23(6 Pt 2):450–452.
- Piconi C, Maccauro G. Zirconia as a ceramic biomaterial. *Biomaterials* 1999;20:1–25.
- Kohal RJ, Klaus G, Strub JR. Zirconia-implant-supported all-ceramic crowns withstand long-term load: a pilot investigation. *Clin Oral Implants Res* 2006;17:565–571.
- Blaschke C, Volz U. Soft and hard tissue response to zirconium dioxide dental implants – a clinical study in man. *Neuro Endocrinol Lett* 2006;27(suppl 1):69–72.
- Piconi C, Burger W, Richter HG, Cittadini A, Maccauro G, Covacci V, et al. Y-TZP ceramics for artificial joint replacements. *Biomaterials* 1998;19:1489–1494.
- Raigrodski AJ, Chiche GJ, Potiket N, Hochstedler JL, Mohamed SE, Billiot S, et al. The efficacy of posterior three-unit zirconium-oxide-based ceramic fixed partial dental prostheses: a prospective clinical pilot study. *J Prosthet Dent* 2006;96:237–244.
- Canullo L, Morgia P, Marinotti F. Preliminary laboratory evaluation of bicomponent customized zirconia abutments. *Int J Prosthodont* 2007;20(5):486–488.
- Rekow D, Thompson V. Engineering long-term clinical success of advanced ceramic prostheses. *J Mater Sci: Mater Med* 2007;18:47–56.
- Silva NR, Coelho PG, Fernandes CA, Navarro JM, Dias RA, Thompson VP. Reliability of one-piece ceramic implant. *J of Biomed Mater Res B Appl Biomater* 2009;88:419–426.
- Silva NR, Nourian P, Coelho PG, Rekow ED, Thompson VP. Impact Fracture Resistance of Two Titanium-Abutment Systems Versus a Single-Piece Ceramic Implant. *Clin Implant Dent Relat Res* 2009;Epub ahead of print.
- Andreiotelli M, Kohal RJ. Fracture strength of zirconia implants after artificial aging. *Clin Implant Dent Relat Res* 2009;11:158–166.
- Kohal RJ, Klaus G, Strub JR. Zirconia-implant-supported all-ceramic crowns withstand long-term load: a pilot investigation. *Clin Oral Implants Res* 2006;17:565–571.
- Haraldson TCG, Ingervall B. Functional state, bite force and postural muscle activity in patients with





- osseointegrated oral implant bridges. *Acta Odontol Scand* 1979;37:195–206.
16. Wenz HJ, Bartsch J, Wolfart S, Kern M. Osseointegration and clinical success of zirconia dental implants: a systematic review. *Int J Prosthodont* 2008;21:27–36.
  17. Chevalier J. What future for zirconia as a biomaterial? *Biomaterials* 2006;27(4):535–543.
  18. Chevalier J, Gremillard L, Deville S. Low-temperature degradation of zirconia and implications for biomedical implants. *Annu Rev Mater Res* 2007;37:1–32.
  19. Fischer-Brandies E, Pratzel H, Wendt T. Zur radioaktiven belastung durch implantate aus Zirkonoxid. *Dtsch Zahnärztl Z* 1991;46:688–690.
  20. Covacci V, Bruzzese N, Maccauro G, Andreassi C, Ricci GA, Piconi C, et al. In vitro evaluation of the mutagenic and carcinogenic power of high purity zirconia ceramic. *Biomaterials* 1999;20:371–376.
  21. Takamura K, Hayashi K, Ishinishi N, Yamada T, Sugiooka Y. Evaluation of carcinogenicity and chronic toxicity associated with orthopedic implants in mice. *J Biomed Mater Res* 1994;28:583–589.
  22. Burger W, Richter HG, Piconi C, Vatteroni R, Cittadini A, Boccalari M. New Y-TZP powders for medical grade zirconia. *J Mater Sci Mater Med* 1997;8:113–118.
  23. Scarano A, Di Carlo F, Quaranta M, Piattelli A. Bone response to zirconia ceramic implants: an experimental study in rabbits. *Journal of Oral Implantology* 2003;29:8–12.
  24. Akagawa Y, Ichikawa Y, Nikai H, Tsuru H. Interface histology of unloaded and early loaded partially stabilized zirconia endosseous implant in initial bone healing. *J Prosthet Dent* 1993;69:599–604.
  25. Akagawa Y, Hosokawa R, Sato Y, Kamayama K. Comparison between freestanding and tooth-connected partially stabilized zirconia implants after two years' function in monkeys: a clinical and histologic study. *Journal of Prosthetic Dentistry* 1998;80:551–558.
  26. Sennerby L, Dasmah A, Larsson B, Iverhed M. Bone tissue responses to surface-modified zirconia implants: A histomorphometric and removal torque study in the rabbit. *Clin Implant Dent Relat Res* 2005;(suppl 1S):13–20.
  27. Hoffmann O, Angelov N, Gallez F, Jung RE, Weber FE. The zirconia implant-bone interface: a preliminary histologic evaluation in rabbits. *Int J Oral Maxillofac Implants* 2008;23:691–695.
  28. Depprich R, Zipprich H, Ommerborn M, Naujoks C, Wiesmann HP, Kiattavorncharoen S, et al. Osseointegration of zirconia implants compared with titanium: an in vivo study. *Head Face Med* 2008;4:30.
  29. Lee J, Sieweke JH, Rodriguez NA, Schüpbach P, Lindström H, Susin C, et al. Evaluation of nanotechnology-modified zirconia oral implants: a study in rabbits. *J Clin Periodontol* 2009;36:610–617.
  30. Kohal RJ, Wolkewitz M, Hinze M, Han JS, Bächle M, Butz F. Biomechanical and histological behavior of zirconia implants: an experiment in the rat. *Clin Oral Implants Res* 2009;20:333–339.
  31. Rocchietta I, Fontana F, Addis A, Schupbach P, Simon M. Surface-modified zirconia implants: tissue response in rabbits. *Clin Oral Implants Res* 2009;20:844–850.
  32. Oliva J, Oliva X, Oliva JD. One-year follow-up of first consecutive 100 zirconia dental implants in humans: A comparison of 2 different rough surfaces. *Int J Oral Maxillofac Implants* 2007;22:430–435.
  33. Oliva J, Oliva X, Oliva JD. Five-year success rate of 831 consecutively placed zirconia dental implants in humans: a comparison of three different rough surfaces. *Int J Oral Maxillofac Implants* 2010;25:336–344.
  34. Lambrich M, Iglhaut G. Vergleich der Überlebensrate von Zirkondioxid- und Titanimplantaten. *Zeitschrift für Zahnärztliche Implantologie* 2008;24:182–91.
  35. Rompen E, Raepsaet N, Domken O, Touati B, Van Dooren E. Soft tissue stability at the facial aspect of gingivally converging abutments in the esthetic zone: a pilot clinical study. *J Prosthet Dent* 2007;97(6 suppl):s119–125.
  36. Rompen E, Touati B, Van Dooren E. Factors influencing marginal tissue remodeling around implants. *Pract Proced Aesthet Dent* 2003;15:754–757, 759, 761.
  37. Tjan AH, Miller GD, The JG. Some esthetic factors in a smile. *J Prosthet Dent* 1984;51:24–28.
  38. Garber DA, Salama MA, Salama H. Immediate total tooth replacement. *Compend Contin Educ Dent* 2001;22:210–6, 218.
  39. Berglundh T, Lindhe J. Healing around implants placed in bone defects treated with Bio-Oss. An experimental study in the dog. *Clin Oral Implants Res* 1997;8:117–124.
  40. Grunder U. Crestal ridge width changes when placing implants at the time of tooth extraction with and without soft tissue augmentation after a healing period of 6 months: report of 24 consecutive cases. *Int J Periodontics Restorative Dent* 2011;31:9–17.
  41. Schneider D, Grunder U, Ender A, Hammerle CH, Jung RE. Volume gain and stability of peri-implant tissue following bone and soft tissue augmentation: 1-year results from a prospective cohort study. *Clin Oral Implants Res* 2011;22:28–37.

## Queries

1. The same research team<sup>11</sup> evaluated fatigue reliability of **as-received** compared to zirconia implants with **coronal** portions prepared by diamond burs – what do you mean by as-received?
2. **not HA coated** – what does this mean?
3. Van Dooren E, Rompen E and Touati B, unpublished data – what year was this?
4. Figure legends 3 to 10 are missing, please provide text.