

Smile Design

Nicholas C. Davis, DDS, MAGD*

*Loma Linda University, School of Dentistry, 11092 Anderson Street,
Loma Linda, CA 92354, USA*

Smile design refers to the many scientific and artistic principles that considered collectively can create a beautiful smile. These principles are established through data collected from patients, diagnostic models, dental research, scientific measurements, and basic artistic concepts of beauty. From the patient's perspective, beauty measures that individual's perception of beauty as noted in the saying: "Beauty is in the eye of the beholder." That perception of beauty may also be influenced by cultural, ethnic, or racial concepts of beauty and may vary from the standards established in the North American dental community.

When planning treatment for esthetic cases, smile design cannot be isolated from a comprehensive approach to patient care. Achieving a successful, healthy, and functional result requires an understanding of the interrelationship among all the supporting oral structures, including the muscles, bones, joints, gingival tissues, and occlusion. Gaining this understanding requires collecting all the data necessary to properly evaluate all the structures of the oral complex.

A comprehensive dental examination should include dental radiographs, mounted diagnostic models, photographic records, and a thorough clinical examination and patient interview. The clinical examination should include a smile analysis and the evaluation of the teeth, temporomandibular joints, occlusion, existing restorations, periodontal tissues, and other soft tissues of the oral cavity.

In addition to the esthetics, the function component of the anterior teeth must be considered in treatment planning. Anterior guidance in harmony with healthy joint positions is key in establishing a stable occlusal scheme. The strategic players in anterior guidance are the maxillary cuspids. A cuspid-protected occlusion helps improve the longevity of the occlusion,

* 1194 Morningside Drive, Laguna Beach, CA 92651.

E-mail address: info@smilesbydavis.com

anterior teeth, and aesthetic restorations. It also protects the periodontium by directing the occlusal forces along the long axis of the teeth. Guiding the function to eliminate lateral and occlusal interferences helps prevent fremitus and potential joint issues resulting from traumatic occlusion.

The principles of smile design require an integration of esthetic concepts that harmonize facial esthetics with the dental facial composition and the dental composition. The dental facial composition includes the lips and the smile as they relate to the face. The dental composition relates more specifically to the size, shape, and positions of the teeth and their relationship to the alveolar bone and gingival tissues. Therefore, smile design includes an evaluation and analysis of both the hard and soft tissues of the face and smile ([Appendix 1](#)).

This article focuses on the dental and dental–facial composition involved in smile design. Only basic facial esthetics are reviewed as a guideline for facial analysis. Analyzing, evaluating, and treating patients for the purpose of smile design often involve a multidiscipline approach to treatment. Specialty treatment for achieving an ideal smile can include orthodontics; orthognathic surgery; periodontal therapy, including soft tissue repositioning and bone recontouring; cosmetic dentistry; and plastic surgery. This esthetic approach to patient care produces the best dental and dental–facial beauty.

Facial beauty is based on standard esthetic principles that involve the proper alignment, symmetry, and proportions of the face. The basic shape of the face is derived from the scaffolding matrix comprised of the facial bones that form the skull and jaw as well as of the cartilage and soft tissues that overlay this framework.

Facial features in smile design include facial height, facial shape, facial profile, gender, and age. In classical terms, the face height is divided into three equal thirds: from forehead to brow line, from brow line to the base of the nose, and from the base of the nose to the base of the chin. The width of the face is typically the width of five “eyes” ([Fig. 1](#)) [1]. As viewed from the frontal position, the four basic facial shapes recognized in the Trubyte denture tooth mold selection guide are square, tapering, square tapering, and ovoid. Lateral facial profiles can be straight, convex, or concave. A cephalometric analysis of the head in frontal and lateral views is useful in determining bony relationships of the face and the mandible, and their relationship to the teeth in the alveolar bone. The facial features related to gender and age involve the soft tissues and include the texture, complexion, and tissue integrity of the epithelial tissues.

Facial features that have a particularly important impact on the dental–facial composition are those that relate the interpupillary plane with the commissure line and the occlusal plane [2]. The interpupillary line should be parallel with the horizon line and perpendicular to the midline of the face. In addition, the interpupillary line should be parallel with the commissure line and occlusal plane [3].

Lip analysis is another important soft tissue feature helpful in evaluating the dental–facial composition and establishing a smile design. The lips play




Fig. 1. Classical face proportions. (Courtesy of Nicholas C. Davis, DDS, MAGD, Loma Linda, CA.)

an important role in that they create the boundaries of the smile design's influence. Understanding lip morphology and lip mobility can often be helpful in meeting patients' expectations and determining the criteria for success.

Genetic traits; the position of the teeth, alveolar bone, and jaws; and their relationships influence the shape of the lips. The upper lip is somewhat more arched and wider than the lower lip. Because the maxillary arch with the teeth overlaps the mandibular arch, the upper lip is the longer of the two. The lower lip, therefore, is recessed beneath the upper lip approximately 30° in relation to the upper lip when the arches are properly aligned [4].

There are three aspects of the lip morphology that should be considered: width, fullness, and symmetry. Wide lips make for a wide smile. In general terms, a smile that is at least half the width of the face, at that level of the face, is considered esthetic. The fullness and symmetry of the upper and lower lips should also be documented. The fullness of the lip, or lip volume, can be categorized as full, average, or thin. Lip symmetry involves the mirror image appearance of each lip when smiling.

The upper and lower lips should be analyzed separately and independently of one another. Independent evaluation of the upper and lower lip is essential when analyzing both symmetry and fullness. The question should be asked: "Are the upper and lower lips symmetric on both sides of the midline and do they have the same degree of fullness?" In Fig. 2A, the upper and lower lips are symmetric but they differ in fullness. In Fig. 2B the upper lip is asymmetric and the lower lip is symmetric and the fullness is similar. Recognizing the etiology of lip asymmetries is helpful in determining if there

is a dental solution for improvement or if plastic surgery is necessary. Sometimes both are necessary to provide the results desired by the patient.

The position of the lips in the rest position should be evaluated for lip contact as well as for the range of lip mobility when smiling. These two determinants establish how much tooth structure and gingival tissue are revealed when comparing the repose and full smile positions. Evaluating this dental–facial feature can be helpful in analyzing and determining treatment modalities necessary to improve the smile. Lip evaluation is also useful when considering the patient’s expectation and, more importantly, for revealing tooth and tissue asymmetries or defects.

When smiling, the inferior border of the upper lip as it relates to the teeth and gingival tissues is called the lip line. An average lip line exposes the maxillary teeth and only the interdental papillae. A high lip line exposes the teeth in full display as well as gingival tissues above the gingival margins. A low lip line displays no gingival tissues when smiling. In most cases, the lip line is acceptable if it is within a range of 2 mm apical to the height of the gingiva on the maxillary centrals [5].

In cases where there is a high lip line and an excessive gingival display exists, an unwanted “gummy smile” becomes evident. Several corrective options are available, depending on conditions and patient limitations. With cephalometric analysis, vertical maxillary excess can be determined. Orthodontics and orthognathic surgery to impact the maxilla are ideal when these conditions are confirmed as skeletal displasias in nature.

In other cases where apparent diminished tooth size in combination with a high lip line creates a gummy smile, corrective periodontal procedures are

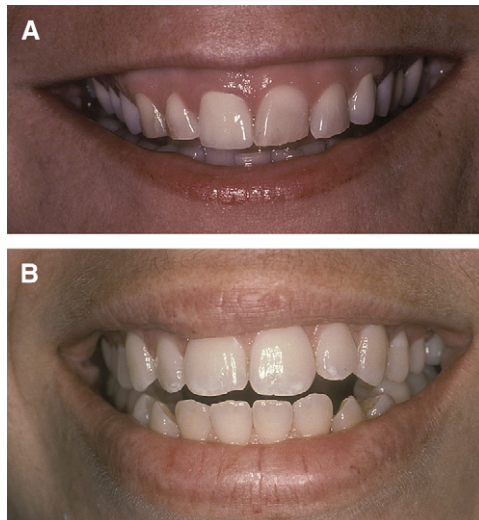

Fig. 2. (A) The upper and lower lips are symmetric but they differ in fullness. (B) The upper lip is asymmetric. (Courtesy of Nicholas C. Davis, DDS, MAGD, Loma Linda, CA.)

an option [6]. This involves cases where altered passive eruption makes a normal-sized tooth appear small. Altered passive eruption occurs when the pellicle does not completely recede to the cemento-enamel junction [6]. As a result, the tooth appears short because the gingival portion of the enamel, which is usually exposed, remains covered with gingival tissues.

Cosmetic crown lengthening to expose the covered enamel can improve normal tooth height and tooth proportions. This can produce a more pleasing emergence profile of the tooth. These procedures can also be helpful in creating symmetry, positive radicular architecture, and proper zenith points of the gingival margins. Many times when exostoses exists, recontouring the alveolar bone is also necessary to recreate and define normal architecture and prevent a ledging appearance of the gingival tissues.

The frenum attachment can also affect the upper-lip shape and the amount of tooth exposure. In such cases, especially where the attachment is broad, a frenectomy that is dissected out from origin to insertion, removing the elastic fibers, can also free up the lip for normal lip movement. This can also be useful when a redundant flap of tissue, termed by this author as a “lip curtain” (Fig. 3), is visible hanging beneath the upper lip when smiling. These procedures, used in combination with cosmetic dental procedures, can reduce gummy smiles and produce a more esthetic smile (Fig. 4).

The incisal display refers to the amount of visible tooth displayed when the lips and lower jaw are in the rest position. The average incisal display of the maxillary centrals for males is 1.91 mm and the average for females is 3.40 mm [2]. With age, the amount of incisal display of the maxillary centrals diminishes and the amount of incisal display of the mandibular centrals increases [7]. Therefore, the amount of incisal display is an important factor in a youthful smile.

The inferior border of the upper lip and the superior border of the lower lip form an outline of the space that is revealed when smiling. The curvature of the lips as well as the prevalence of the shapes formed by the lips has been noted in texts [2]. The space that includes the teeth and tissues is called the smile zone [8]. There are six basic smile-zone shapes: straight, curved,

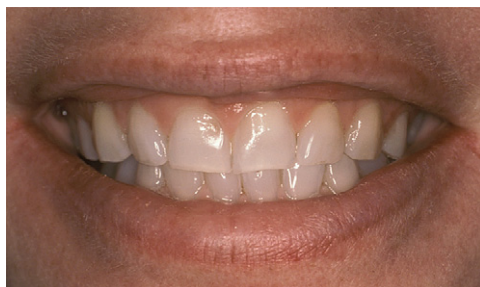

Fig. 3. A broad attachment of frenum creates second band of tissue, a “lip curtain,” below the lip. (Courtesy of Nicholas C. Davis, DDS, MAGD, Loma Linda, CA.)

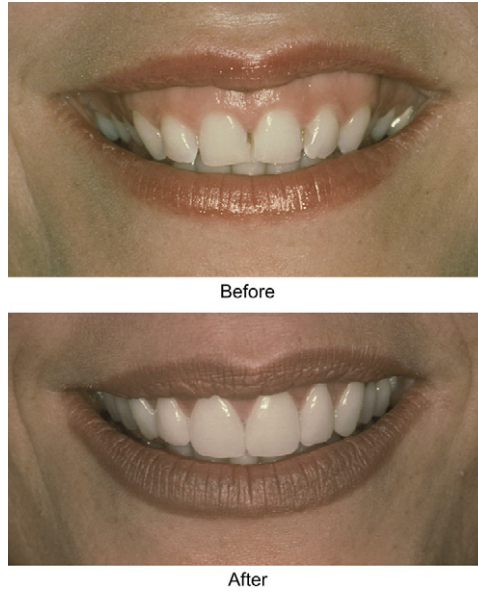

Fig. 4. Before (*top*) and after (*bottom*) crown lengthening, frenectomy and application of 10 maxillary porcelain veneers. (*Courtesy of* Nicholas C. Davis, DDS, MAGD, Loma Linda, CA.)

elliptical, bow-shaped, rectangular, and inverted (Fig. 5). The first three shapes are the most common. Identifying these shapes is helpful in analyzing the smile.

A feature of smile design that is often overlooked yet very significant is the health, symmetry, and architecture of the gingival tissues. These tissues frame the teeth and add to the symmetry of the smile. The health and subsequent color and texture of these gingival tissues are paramount for long-term success and the esthetic value of the treatment.

Healthy gingival tissues are pale pink and can vary in degree of vascularity, epithelial keratinization, and pigmentation, and in the thickness of the epithelium. The papillary contour should be pointed and should fill the interdental spaces to the contact point. An unfilled interdental space creates an unwanted black interdental triangle in the gingival embrasure and makes a smile less attractive (Fig. 6). Managing the soft tissues in this area improves the smile when these tissues are revealed. The architecture has a positive radicular shape forming a scalloped appearance that is symmetric on both sides of the midline. The marginal contour of the gingival should be sloped coronally to the end in a thin edge. The texture of the tissues should be stippled (orange-peel-like appearance) in most cases. The stippling may be fine or coarse and the degree of stippling varies. In younger females, the tissue is more finely textured and has a finer stippling when compared with that of males. The tissue should be firm in consistency and the attached part

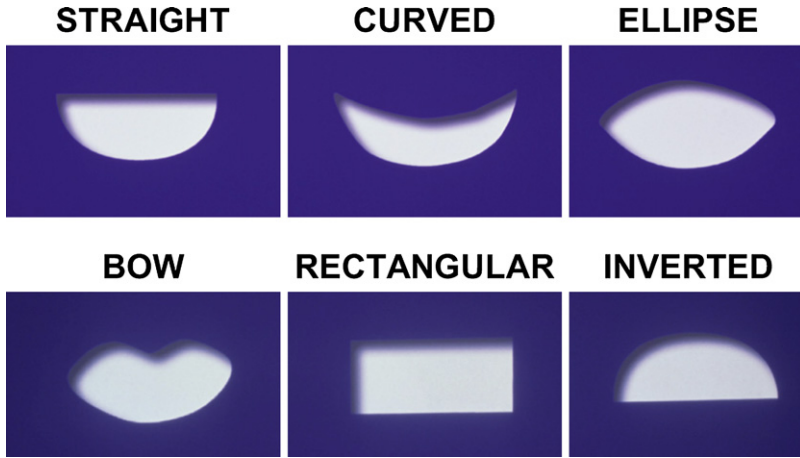


Fig. 5. Smile zone shapes. (Courtesy of Nicholas C. Davis, DDS, MAGD, Loma Linda, CA.)

should be firmly anchored to the teeth and underlying alveolar bone. A normal, healthy gingival sulcus should not exceed 3 mm in depth [6].

The gingival contours should be symmetric and the marginal gingival tissues of the maxillary anterior teeth should be located along a horizontal line extending from cuspid to cuspid. Ideally, the laterals reach slightly short of that line (Fig. 7) [5]. It is also acceptable, although not ideal, to have the gingival height of all six anteriors equal in gingival height on the same plane (Fig. 8). In such cases, however, the smile may appear too uniform to be esthetically pleasing. A gingival height of the laterals that is more apical to the centrals and cuspids is considered unattractive (Fig. 9).

The gingival zenith point is the most apical point of the gingival tissues along the long axis of the tooth. Clinical observations along with a review of diagnostic models reveal that this most apical point is located distal to the long axis on the maxillary centrals and cuspids (Fig. 10). The zenith point of the maxillary laterals and the mandibular incisors is coincident with the long axis of these teeth (Fig. 11) [2].

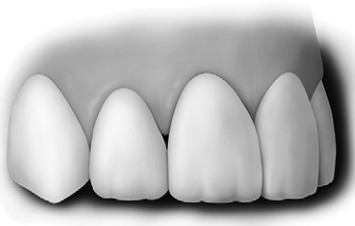


Fig. 6. The black triangle is presenting the cervical embrasure between the central and lateral. (Courtesy of American Academy of Cosmetic Dentistry, Madison, WI; with permission.)

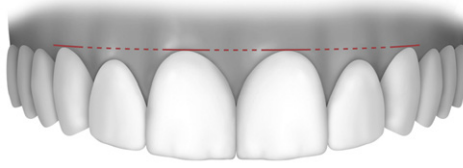


Fig. 7. The gingival margins of the centrals and cuspids are apical to that of the laterals. This appearance is considered more attractive than those shown in Figs. 8 and 9. (Courtesy of American Academy of Cosmetic Dentistry, Madison, WI; with permission.)

An attractive smile line is one of the most important features of a pleasing smile. The smile line can be defined as an imaginary line drawn along the incisal edges of the maxillary anterior teeth. In an ideal tooth arrangement, that line should coincide or follow the curvature of the lower lip while smiling (Fig. 12) [9]. Another frame of reference suggests that the centrals are slightly longer than the cuspids. In a reverse smile line, the centrals appear shorter than the cuspids along the incisal plane and create an aged or worn appearance (Fig. 13) [5].

Texts differ on the best height for a maxillary central incisor. One text records the average height from the cemento-enamel margin to the incisal edge as 10.5 mm. The importance of tooth length has been recognized and documented in tooth measurement tables recorded by Dr. G.V. Black. In those tables the average height of a maxillary central was noted as 10 mm with the greatest being 12 mm and the least being 8 mm [10]. Another text records the crown height of a maxillary unworn central incisor ranging from 11 to 13 mm with the average height being 12 mm [2].

For esthetic purposes, the height of the central incisors can vary depending upon the incisal display and the influence of the smile line. Other guidelines for determining the dimensions of the maxillary central incisors include the following:

Central incisor length is approximately one sixteenth of the facial height. The ratio of width to height is 4:5 or 0.8:1. In general, the accepted range for the width of the central is 75% to 80% of the height (Fig. 14).

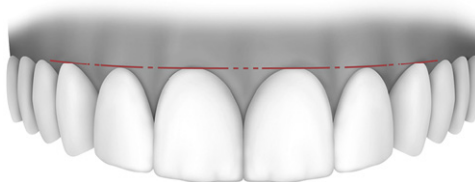


Fig. 8. Similar gingival heights of the six anterior teeth are acceptable although not considered ideal. (Courtesy of the American Academy of Cosmetic Dentistry, Madison, WI; with permission.)

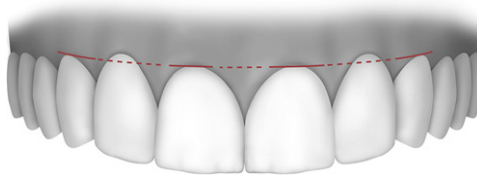


Fig. 9. When the gingival margins of the lateral is apical to that of the centrals, cuspids, or both, the anterior gingival relationship is considered unattractive. (Courtesy of American Academy of Cosmetic Dentistry, Madison, WI; with permission.)

The centrals are most likely too long if they interfere or impinge on the lower lip causing dimpling or entrapment during the formation of the “F” and “V” sounds.

The length of the incisors can also be evaluated using the occlusion. The central is most likely too short or positioned wrong if it is short of a line drawn from the mesial buccal cusp tip of the maxillary first molar and the cusp tip of the cuspid [5].

There are several other considerations when attempting to reestablish normal tooth height, depending on the etiology of the diminished tooth size. Occlusal discrepancies, closed vertical dimension, anterior wear, poor bone and joint relationships, and parafunctional habits can all be considered causative factors. The correct diagnosis leads to the most suitable treatment options for long-term success and stability. In many instances, orthodontic treatment or orthognathic surgery is required before treatment. In other cases, full mouth reconstruction is necessary, often in concert with orthodontic treatment. Cosmetic crown lengthening is another consideration, depending upon conditions or limitations imposed by the patient.

The relative proportions of the maxillary six anterior teeth to each other is another analytical consideration. Many clinicians accept and apply the principles of the Golden Proportion to dentistry. This concept was first mentioned by Lombardi and later developed by Levin [2]. However, the rigidity of this mathematical formula and the many variables among patients have led to many challenges regarding the reliability of this principle. The Golden Proportion suggests an ideal mathematical proportion of 1:1.618. When applied to dentistry, this relates the apparent widths of the maxillary six anterior teeth from a frontal view. The discrepancy between the apparent width

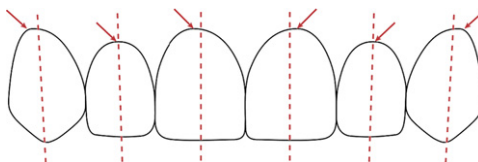


Fig. 10. Gingival shape, zenith point (arrow), and longitudinal axis (dotted lines). (Courtesy of American Academy of Cosmetic Dentistry, Madison, WI; with permission.)

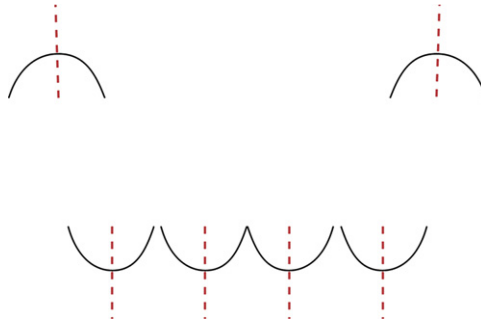


Fig. 11. Gingival shape of maxillary laterals (*upper curved lines*) and mandibular incisors (*lower curved lines*). (Courtesy of American Academy of Cosmetic Dentistry, Madison, WI; with permission.)

and actual width is explained by the positioning of these teeth along the curve of the maxillary arch (Fig. 15) [5]. Using this ratio as a guide to direct treatment is a useful tool in esthetic cases for an ideal smile (Fig. 16).

The midline refers to a vertical line formed by the contact of the maxillary central incisors. The midline should be perpendicular to the incisal plane and parallel or coincident to the midline of the face (Fig. 17). Studies have shown that minor discrepancies between facial and dental midlines are acceptable and that in many cases these discrepancies are not noticeable [11]. A canted midline, however, is a more perceptible deviation from the norm [12] and should be avoided.

Several anatomical landmarks can be useful guides to assess the midline of the face as it relates to dental midline. They include the midline of the nose, forehead, interpupillary plane, philtrum, and chin. Some anatomical landmarks may vary in midline accuracy due to variations in genetic structure, such as chin position and the cartilaginous structure of the nose. The philtrum of the lip is considered to be one of the most accurate of these anatomical guideposts as it is always in the center of the face. The exceptions are surgical, accident, and cleft-lip cases. The center of the philtrum

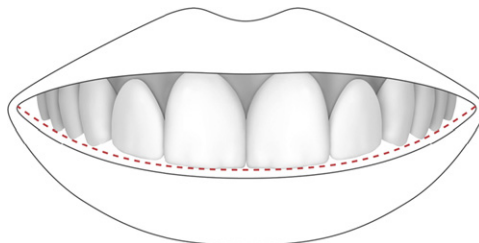


Fig. 12. Ideal smile line. (Courtesy of American Academy of Cosmetic Dentistry, Madison, WI; with permission.)

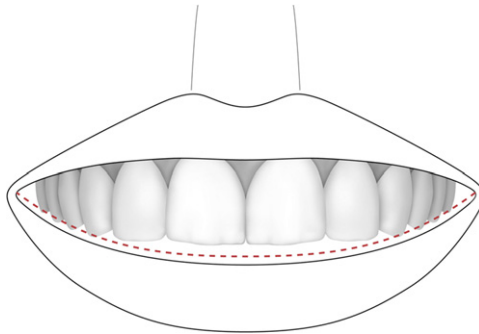


Fig. 13. Reverse smile line. (Courtesy of American Academy of Cosmetic Dentistry, Madison, WI; with permission.)

is the center of Cupid's bow and it matches the papilla between the centrals. This places the central papilla directly over the dental midline [5].

A key element in smile design pivots around the midline as it unites the face and its features with dentition and the anterior teeth in particular. From a frontal view, the axial inclination of the anterior teeth tends to incline mesially toward the midline and become more pronounced from the central incisors to the canines. This inclination is least noticeable with the centrals and becomes more pronounced with the laterals and even more so with the canines. The axial inclination of the posterior teeth from the frontal view exhibits the same mesial inclination toward the midline as the cuspid. This also creates a natural visual gradation, making the teeth appear to diminish in size as they progress posteriorly (Fig. 18) [2].

Once again, the lips together with the teeth form another esthetic area that should be considered in smile design. The area between the corners of the mouth during smile formation and the buccal surfaces of the maxillary teeth (particularly the bicuspid and molars) form a space known as the buccal corridor. The greater and more pronounced this negative space becomes, the more these posterior teeth are concealed, restricting the full breadth of the smile (Fig. 19). A full and symmetric buccal corridor is an important element of an esthetic smile. The buccal corridor should not be

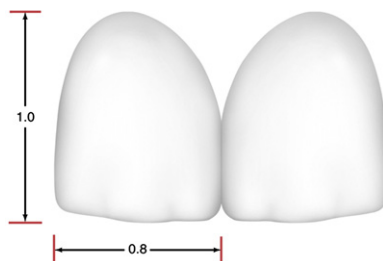


Fig. 14. Proportion of centrals. (Courtesy of American Academy of Cosmetic Dentistry, Madison, WI; with permission.)

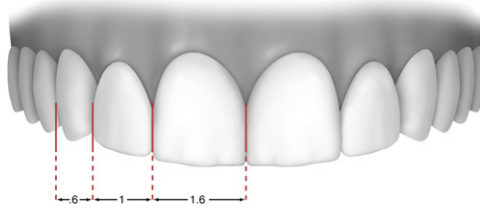
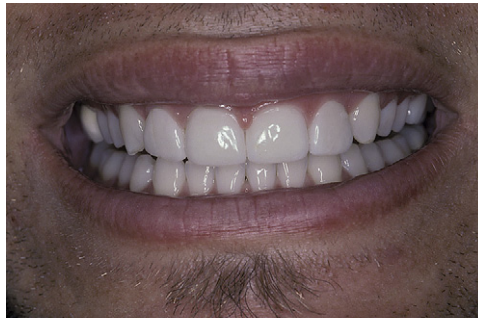

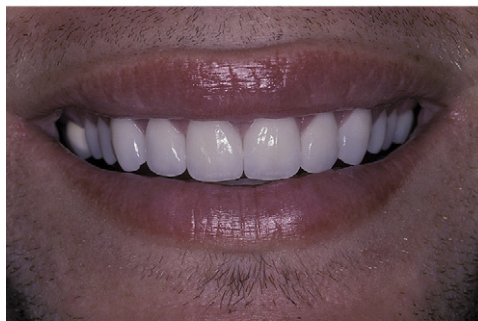Fig. 15. Golden Proportion. (*Courtesy of American Academy of Cosmetic Dentistry, Madison, WI; with permission.*)

completely eliminated because a hint of negative space imparts a suggestion of depth to the smile [2].

Several factors influence the appearance of the buccal corridor. These factors include the width of the smile and the maxillary arch. Other factors include the tonicity of facial muscles and individual smiling characteristics; the position of the labial surfaces of the maxillary bicuspids; the predominance of the cuspids, particularly at the distal facial line angle; and any discrepancy between the value of the bicuspids and the six anterior teeth. This negative space is often accentuated when smile rejuvenation is limited to the



Before



After

Fig. 16. Before (*top*) and after (*bottom*) crown lengthening and application of six porcelain veneers, demonstrating application of proper proportions to the maxillary six anterior teeth. (*Courtesy of Nicholas C. Davis, DDS, MAGD, Loma Linda, CA.*)

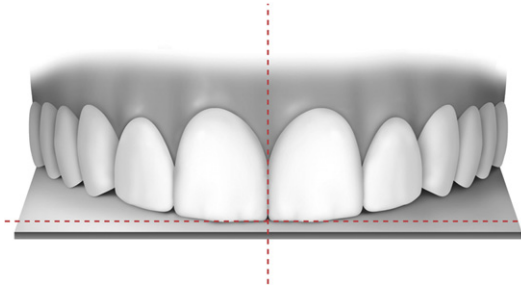


Fig. 17. Midline (*vertical dotted line*). (Courtesy of American Academy of Cosmetic Dentistry, Madison, WI; with permission.)

maxillary six anterior teeth and the hue and value of newly restored teeth do not blend with the untreated teeth (Figs. 20A, B). The result is an unwanted exaggeration of the sense of depth, darkness, and the prominence of the buccal corridor [5].

In these posterior segments, the artistic perception of esthetics can be used to alter the typical inclinations to produce an enhanced esthetic affect. Orthodontically up-righting the posterior teeth can help. Also, through cosmetic dentistry to slightly upright the cuspids and the inclination of the posterior segment, the smile can be made to appear wider (Fig. 21). These inclines should not exceed a perfectly vertical orientation. Also, the harmony of having consistent inclines on each of these posterior teeth remains important. These subtle changes can help create a fuller smile that more completely fills the buccal corridor. By up-righting these teeth, the visual foreshortening is diminished. This makes the teeth appear bigger, producing more reflective surfaces for a broader smile, which is in high demand today.

The anatomy of the anterior teeth plays an important role in a natural appearance and the individuality and personality of a smile. Some anterior teeth are flat and some are convex. Some have a square appearance while others have a fan-shaped appearance. These and other distinctive contours give each patient's smile individuality [13]. The labial contour of these teeth should

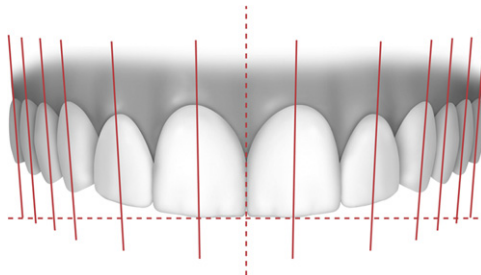


Fig. 18. Axial inclination (*vertical solid lines*). (Courtesy of American Academy of Cosmetic Dentistry, Madison, WI; with permission.)

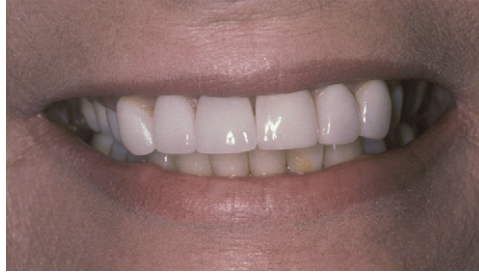

Fig. 19. A dark buccal corridor exists because of the relationship of the anterior teeth with the posterior segments. (*Courtesy of Nicholas C. Davis, DDS, MAGD, Loma Linda, CA.*)

exhibit three planes when viewed from a lateral profile (Figs. 22 and 23) [5]. The surface texture can also add personality to the appearance of the teeth. All of these factors should be considered when restoring teeth in this area.

With ideal anatomy and alignment of these six teeth, an open space is formed between the proximal surfaces of incisal edges from the contact points. This area is called an incisal embrasure. These embrasure spaces terminate at the contact points with the adjacent teeth. The contact areas of both centrals are located at the incisal third of the crowns. Therefore, the incisal embrasure space between the centrals is slight. The contact point between the central and lateral incisor approaches the junction of the middle and incisal thirds of each crown, making it slightly deeper than the junction between the centrals. The contact point of the lateral incisor and the cuspid is approximately at the middle third [10]. Therefore, the incisal embrasure

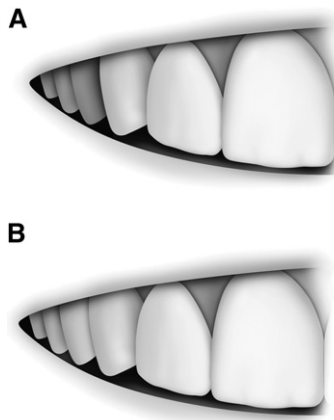


Fig. 20. (A) Shadowing effect of the buccal corridor in the posterior segment when compared with an identical diagram (see Fig. 18B) with properly treated hue and value. (*Courtesy of American Academy of Cosmetic Dentistry, with permission.*) (B) Properly treated buccal corridor demonstrates uniformity in color and alignment of the anterior segment with the posterior teeth in the smile zone. (*Courtesy of American Academy of Cosmetic Dentistry, Madison, WI; with permission.*)

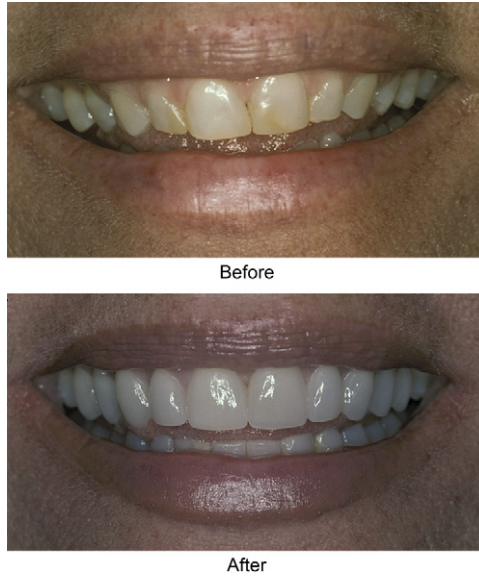

Fig. 21. Before and after crown lengthening, bleaching, and application of 10 porcelain veneers. (Courtesy of Nicholas C. Davis, DDS, MAGD, Loma Linda, CA.)

spaces of the anterior teeth display a natural and progressive increase in depth from the central to the cuspid (Figs. 24 and 25).

Current trends in smile enhancement have demonstrated an appreciation by the public for whiter teeth. According to a recent American Academy of Cosmetic Dentistry survey of dentists in North America conducted by the Levin Group, “Bleaching/Whitening is the most often requested cosmetic service.” Most bleaching experts say the goal is to have the color of the teeth the same as the color of the sclera of the eye. In today’s society, however,

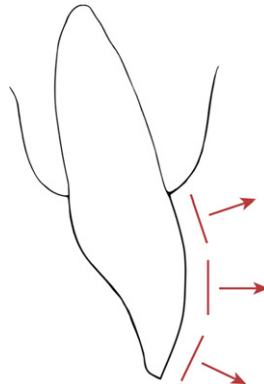


Fig. 22. Labial contour, three planes (cross-sectional view) (lines perpendicular to arrows) (Courtesy of American Academy of Cosmetic Dentistry, Madison, WI; with permission.)

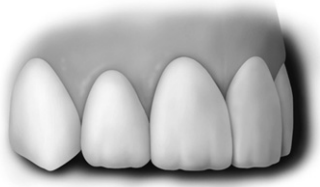

Fig. 23. Labial contour (lateral view). (Courtesy of American Academy of Cosmetic Dentistry, Madison, WI; with permission.)

many patients prefer to have their teeth whiter than what is typically found in nature or beyond what bleaching can provide. For this reason, shade selection of cosmetic enhancement cases must be customized to the satisfaction each patient. Counseling the patient on the natural appearance of teeth and general guidelines for shade selection may also be beneficial to meet the patient's expectations of realism.

Natural-looking teeth are polychromatic in color with the body of the tooth fairly uniform in color and the gingival third more rich in chroma. The incisal portion of the tooth typically exhibits a translucency that can vary from bluish-white to blue, gray, orange and other variations. The variations in the coloration of teeth are due to the anatomy of the physical shape and texture of the individual tooth and the basic anatomy of the dentine and enamel structures of the teeth. Typically, hue, chroma, and value are terms used in describing a color or shade of a tooth. Hue refers to the color or shade, such as red, yellow, or blue. Chroma, which refers to the degree of saturation of a color, describes the different shades of the same color (Fig. 26). Value is the term used to describe the relative brightness of a color. It deals with lightness and darkness and is generally measured on a gray scale (Figs. 27 and 28) [5].

An ideal esthetic treatment plan should be minimally invasive, preserving as much of the natural structures as possible. It should also realign the ideal form and function of the teeth and tissues while enhancing the

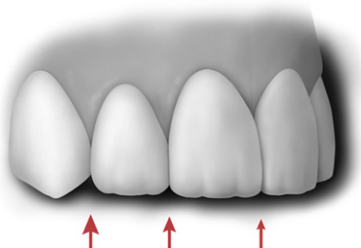


Fig. 24. Incisal embrasures (arrows). Size increases progressively from the central to the cuspid. (Courtesy of American Academy of Cosmetic Dentistry, Madison, WI; with permission.)

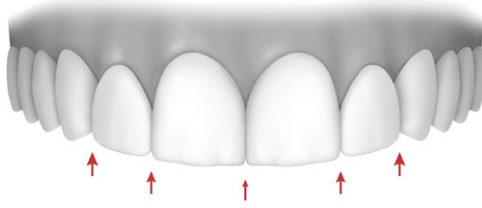


Fig. 25. Incisal embrasures (frontal view) (arrows). (Courtesy of American Academy of Cosmetic Dentistry, Madison, WI; with permission.)

esthetics and should never compromise the patient's oral health or the stability of his or her teeth.

An ideal esthetic treatment plan attempts to achieve perfection in every way. However, not all patients are willing to accept all the components necessary to achieve that level of perfection. In those cases, when compromises become necessary, it is important to review a range of treatment options in an attempt to create the illusion of the ideal while maintaining a healthy oral environment. A cosmetic dental procedure using porcelain veneers is a common method of creating this illusion.

Conducting a patient interview is helpful in determining the patient's expectations and limitations of treatment. In establishing a treatment plan, goals must be set as a way to measure the success of that treatment. A patient's priority may be to have a bright and esthetic smile first while a dentist's goal should be to achieve oral health first. It is not difficult to achieve both. However, maintaining the patient's enthusiasm through the process may be challenging because the proper sequence of treatment to achieve both stated goals may not be what the patient expects. An understanding of the patient's goals and priorities is helpful for the dentist when the treatment plan is established and presented to the patient.

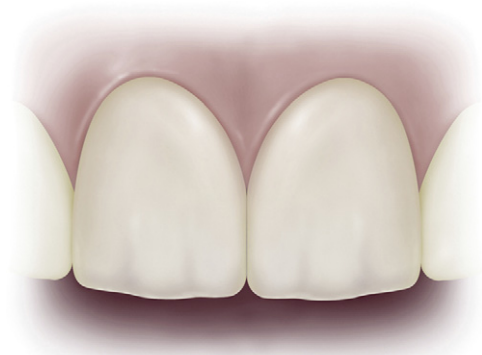


Fig. 26. Color, translucency and color gradient. (Courtesy of American Academy of Cosmetic Dentistry, Madison, WI; with permission.)

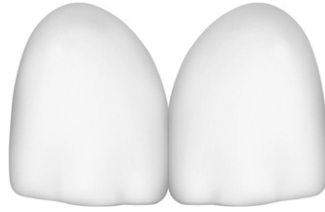

Fig. 27. Both values of the centrals in this example are well matched. (*Courtesy of American Academy of Cosmetic Dentistry, Madison, WI; with permission.*)

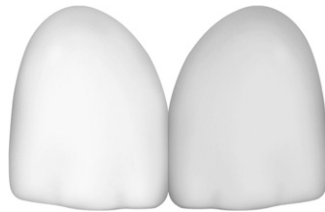

Fig. 28. The value of the central on the right is considered low. (*Courtesy of American Academy of Cosmetic Dentistry, Madison, WI; with permission.*)

This article on smile design did not consider the natural irregularities and random deviations from the norm that contribute to the individuality and beauty of a person's smile. Most beautiful and natural smiles are not necessarily symmetric, uniform in color, or perfect by scientific standards. Consequently, they maintain a natural intrinsic beauty not by the virtue of perfection but rather through the subtle beauty of imperfection. For these reasons, smile design guidelines that use a perfect model as a goal may not necessarily render the most beautiful and natural smile that satisfies both the dentist and patient.

The crafting of an ideal smile requires analyses and evaluations of the face, lips, gingival tissues, and teeth and an appreciation of how they appear collectively. Such an ideal smile depends on the symmetry and balance of facial and dental features. The color, shape, and position of the teeth are all part of the equation. Recognizing that form follows function and that the anterior teeth serve a vital role in the oral health of the patient is paramount. Using a comprehensive approach to diagnosing and treatment planning of esthetic cases can help achieve the smile that best enhances the overall facial appearance of the patient and provides the additional benefit of enhanced oral health.

Acknowledgments

The author thanks the dental team members of the American Academy of Cosmetic Dentistry for their expertise, skills, and help in restoring the

cases used in this article and shown in the Criteria Guide publication of the American Academy of Cosmetic Dentistry. The dental team responsible for treating the cases shown in this article are Dr. Michael Gahagan, periodontist, Newport Beach, California; and Stan Okon, Okon Dental Laboratory, El Toro, California.

Appendix 1

Smile analysis form

Smile Analysis

Name: _____ Date: _____

Patients' Dissatisfaction Areas: _____

Patients' Desires /Limitations: _____

FACIAL FORM: SQUARE OVOID TAPERING SQ. TAPERING **FACIAL PROFILE:**
SMILE ZONE: SHAPE: STRAIGHT CURVED BOW ELLIPSE RECT. INVERTED

DEPTH: SHALLOW AVERAGE DEEP
LIPS:
 THICKNESS: THIN NORMAL FULL
 UPPER:
 LOWER:

SYMMETRY: ASYMMETRIES
 UPPER: NORMAL
 LOWER: NORMAL

WIDTH: NARROW NORMAL WIDE
 BUCCAL CORRIDOR: DARK NORMAL FULL
 NOTES: _____

GINGIVA:

HEALTH: POOR FAIR EXCELLENT
 DISPLAY: NONE PAPILLA MODERATE EXCESSIVE
 ASYMMETRIES:
 NOTES: _____

TEETH:

SMILE LINE LENGTH: LONG NORMAL HIGH
 SMILE LINE SHAPE: STRAIGHT CURVED IRREGULAR
 SHADE: WIDTH OF CENTRALS (7.5 - 9.5) _____ MM HEIGHT OF CENTRALS (11 - 13) _____ MM
 MIDLINE: CENTERED- INCLINATION- LINE ANGLES:
 EXISTING RESTORATIONS: _____

NOTES & Tx. RECOMMENDATIONS: _____

References

- [1] Parramón José M. How to draw heads and portraits. New York: Watson-Guption Publishing; 1989. p. 14–5.
- [2] Rufenacht Claude R. Fundamentals of esthetics. Quintessence Publishing Co.; 1990. p. 73, 80–2, 89, 94, 95, 125–7, 138.
- [3] Rufenacht Claude R. Principles of esthetic integration. Quintessence Publishing Co.; 2000. p. 109–11.
- [4] Hogarth Burne. Drawing the human head. New York: Watson-Guption Publishing; 1989. p. 48.
- [5] Blitz N, Steel C, Willhite C. Diagnosis and treatment evaluation in cosmetic dentistry—a guide to accreditation criteria. Madison (WI): American Academy of Cosmetic Dentistry; 2001. p. 8–10, 16, 28, 32, 34, 46, 47.
- [6] Grant GA, Stern IB, Everett FG. Orban's periodontics. 3rd edition. C.V. Mosby Co; 1968. p. 5–7, 33–5, 387.
- [7] Vig RG, Brundo GC. The kinetics of anterior tooth display. *J Prosthet Dent* 1972;39:502.
- [8] Davis Nicholas C. An artistic approach to smile design. *Dent Today* 1999;18(8):57.
- [9] Ahmad I. Geometric considerations in anterior dental esthetics: restorative principles. *Pract Periodontics Aesthet Dent* 1998;10(7):813–22.
- [10] Wheeler RC. A textbook of dental anatomy and physiology. W.B. Saunders; 1965. p. 102, 103, 126, 131, 427.
- [11] Miller EC, Bodden WR, Jamison HC. A study of the relationship of the dental midline to the facial midline. *J Prosthet Dent* 1979;41:657–60.
- [12] Kokich Vincent O Jr, Kiyak Asuman H, Shapiro Peter A. Comparing the perception of dentists and lay people to altered dental esthetics. *J Esthetic Dent* 1999;11:311–24.
- [13] Dawson PE. Evaluation, diagnosis and treatment of occlusal problems. The C. V, Mosby Company; 1974. p. 173.